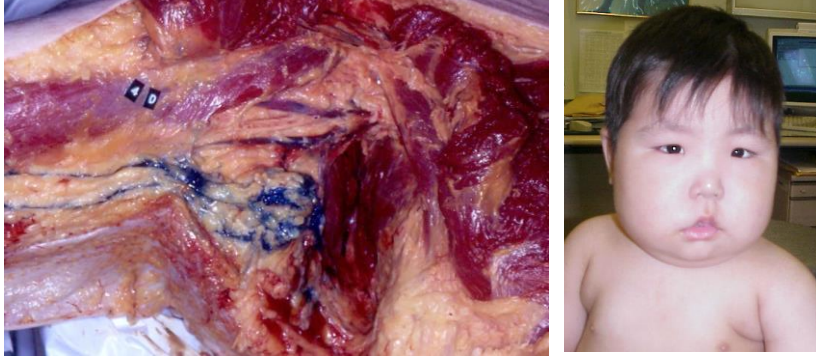
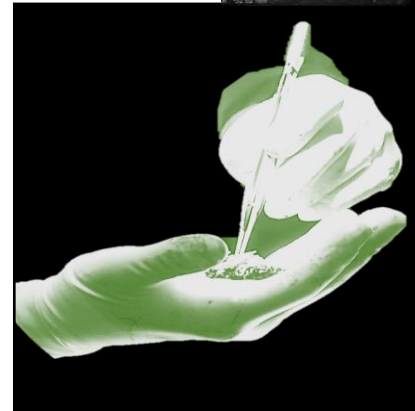
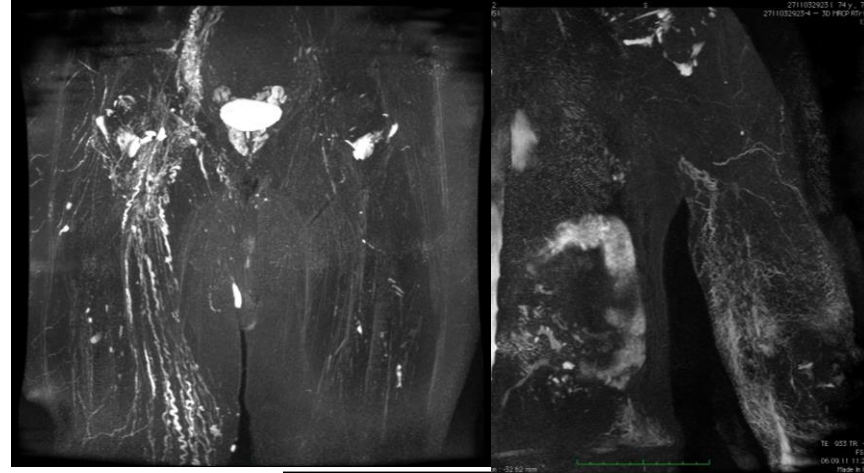


POSSIBLE SURGERIES FOR LYMPHOEDEMA

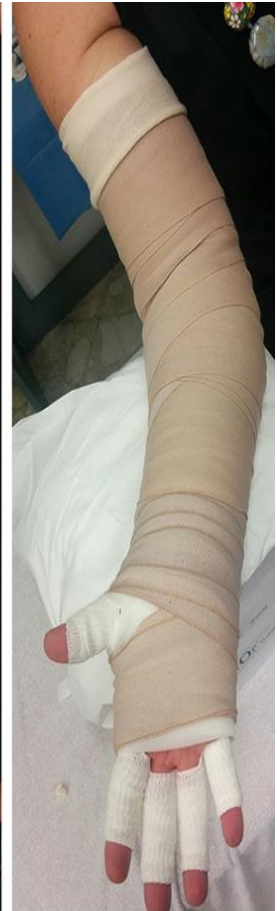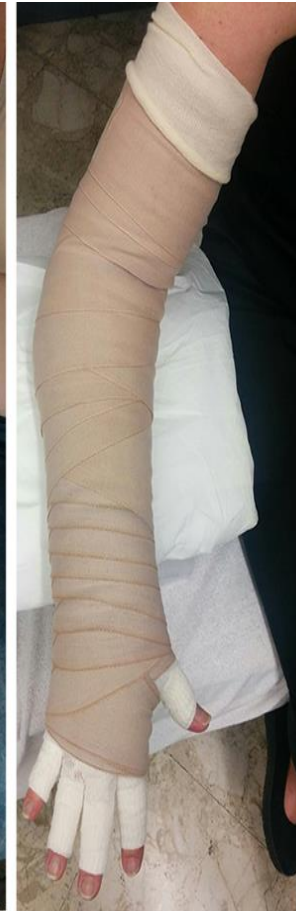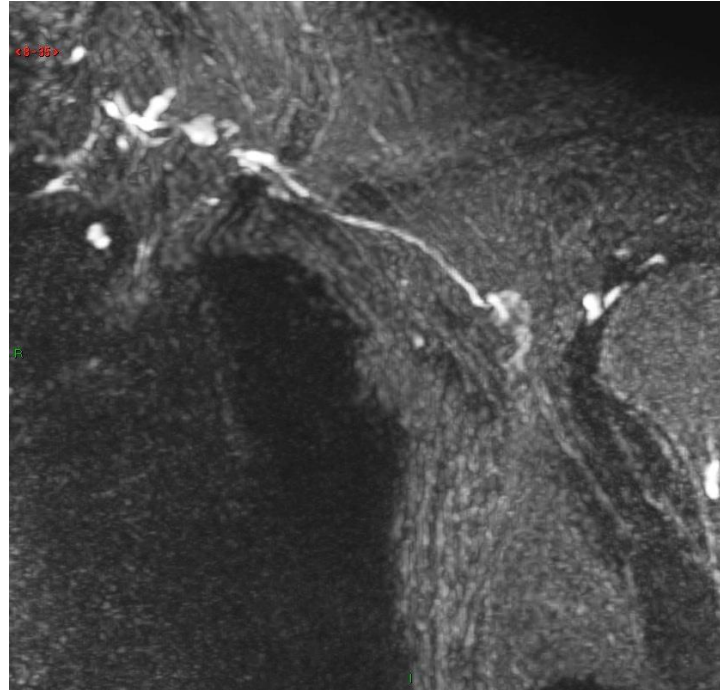
Becker C



MULTI DISCIPLINAIR APPROACH



BANDAGING WHEN PATHWAYS IS THE BEST SOLUTION

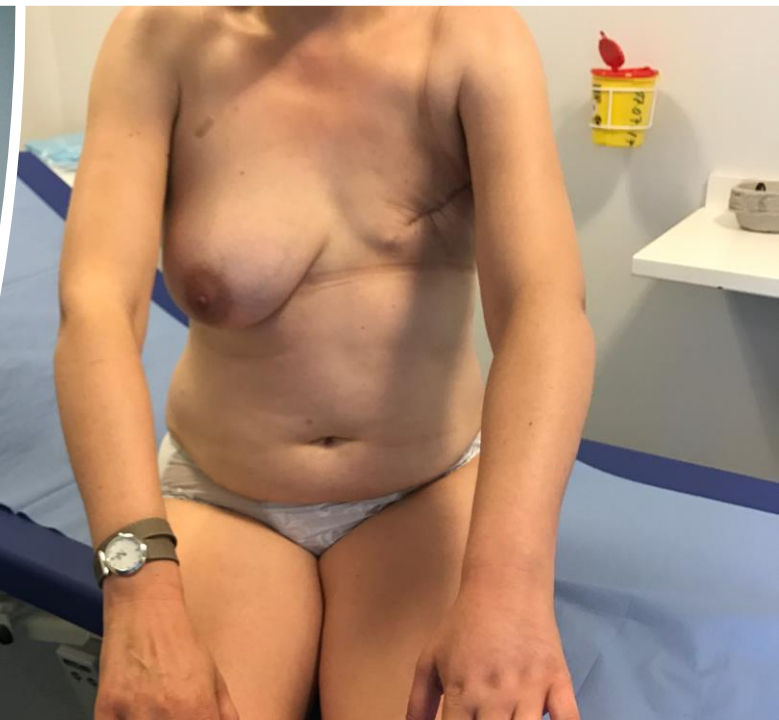
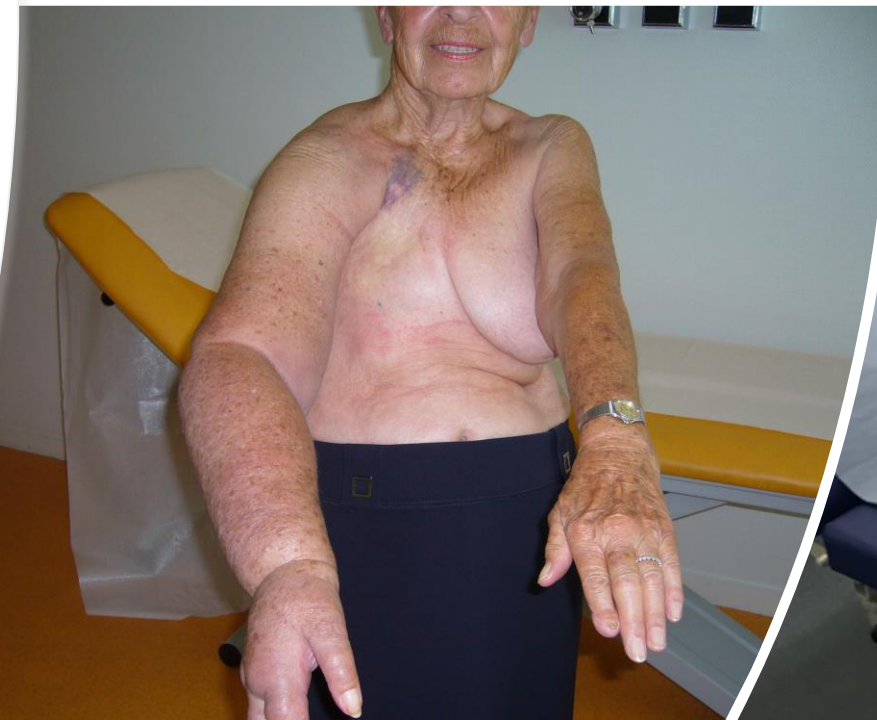
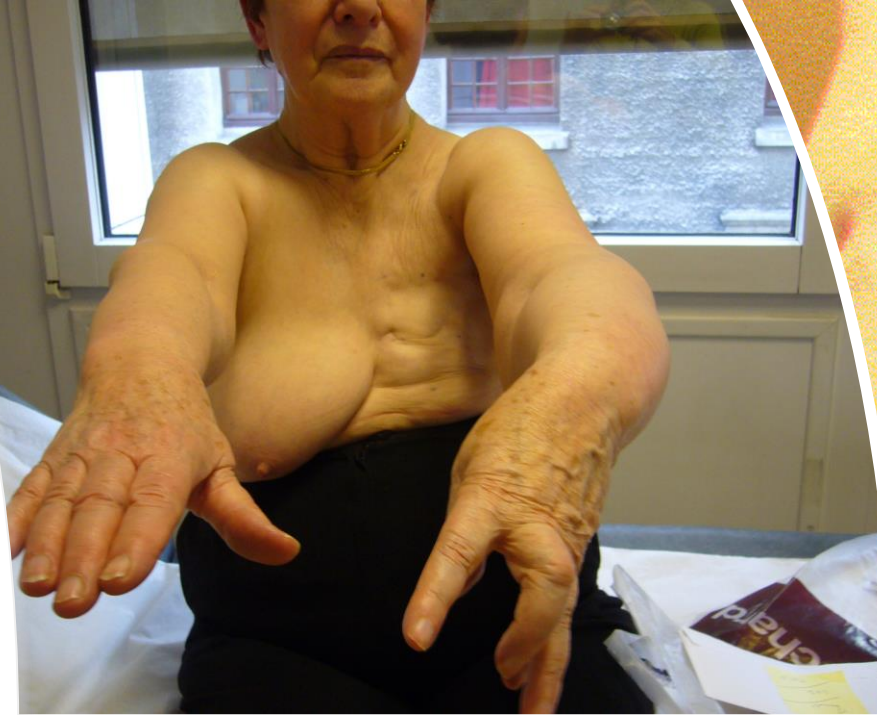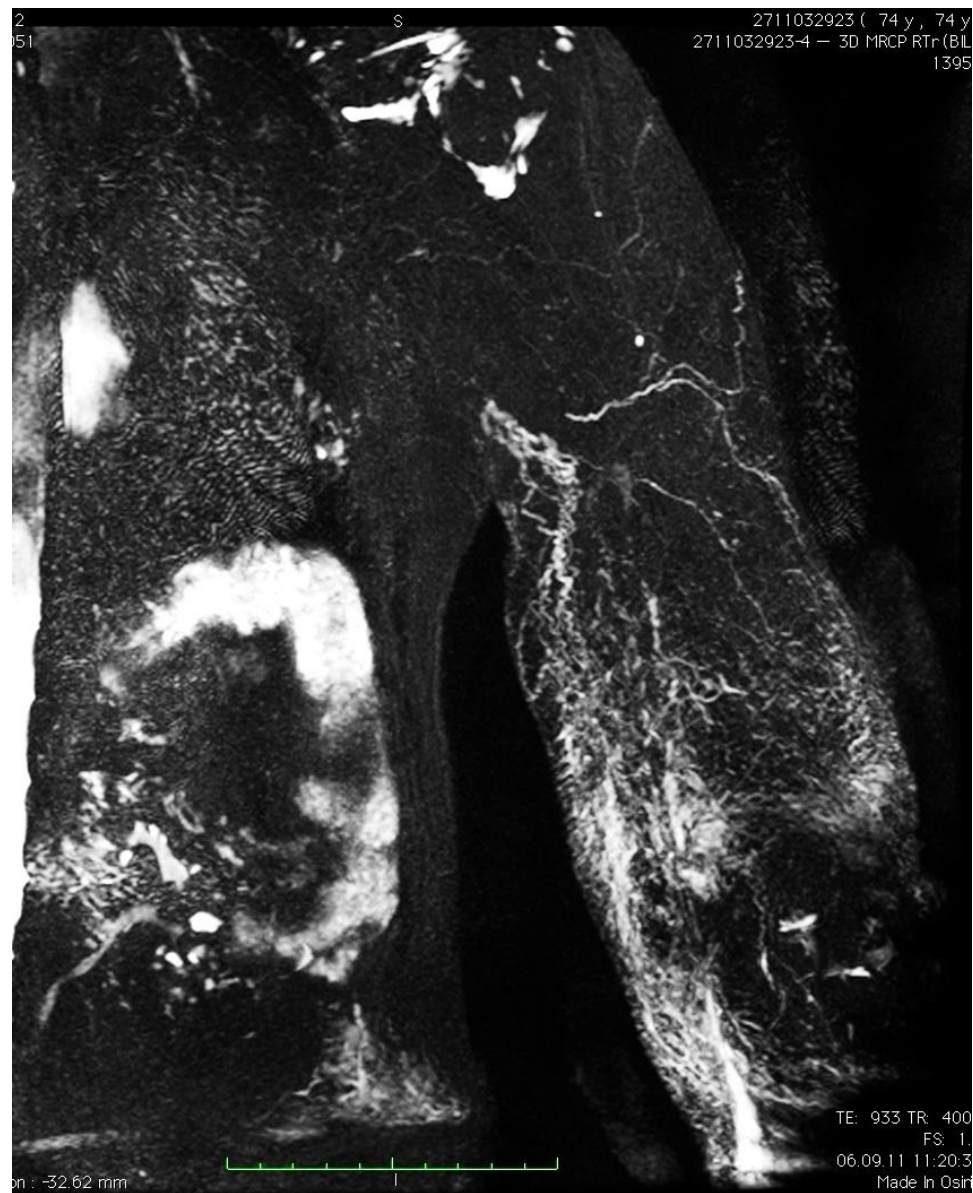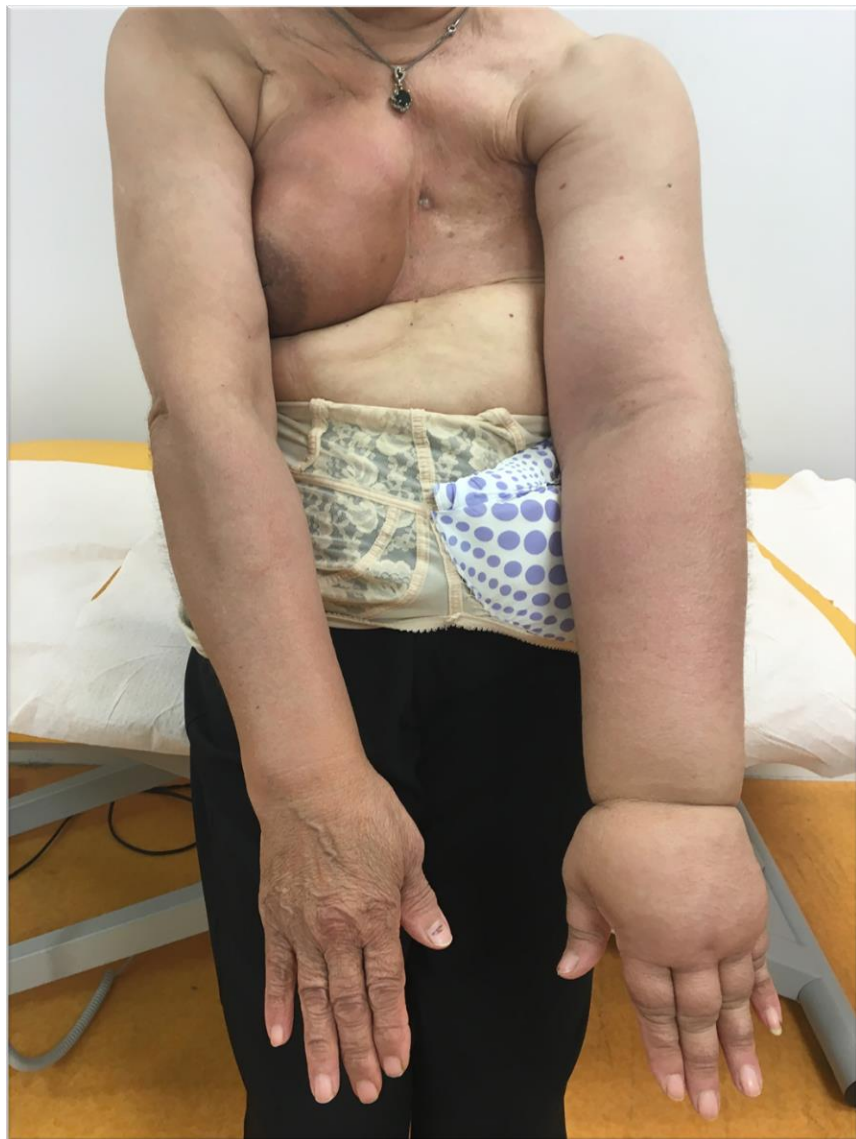**UPPER
EXTREMITY
IATROGENIC**

**LYMPHOEDEMA DIFFERENT
STAGES, FIBROSIS,
INFECTIONS, PALSY ,
BREAST RECONSTRUCTION**

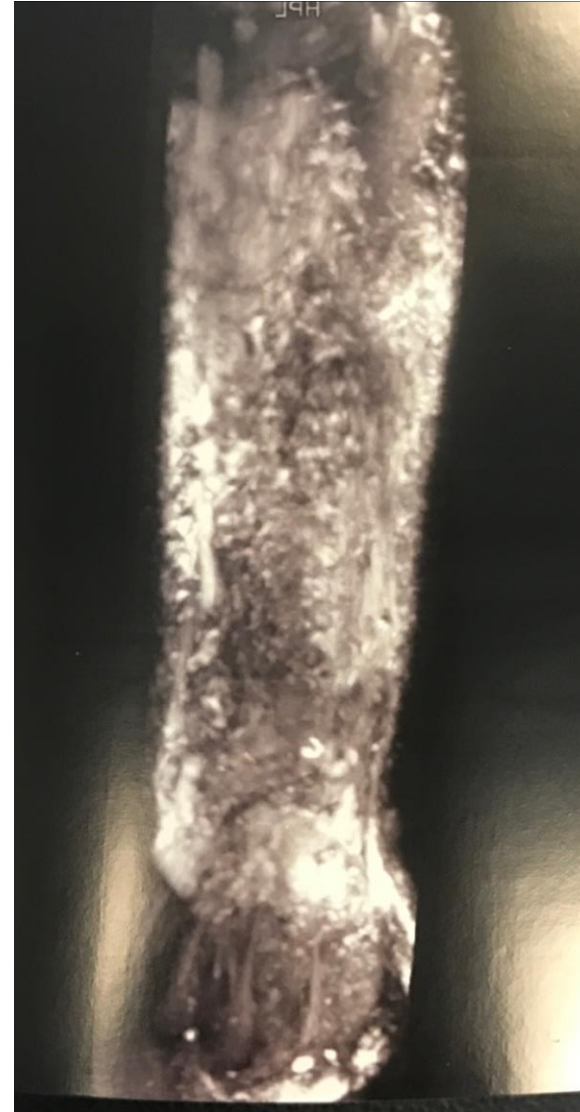
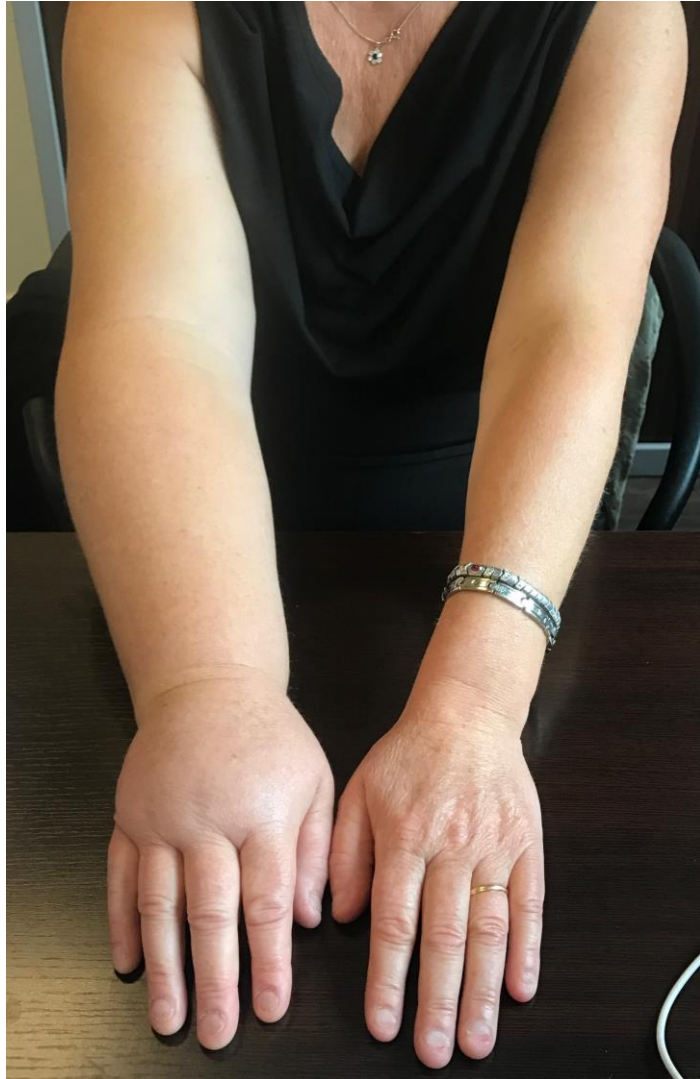...

**LYMPHOMRI AND CLINIC
FOR THE STRATEGY**





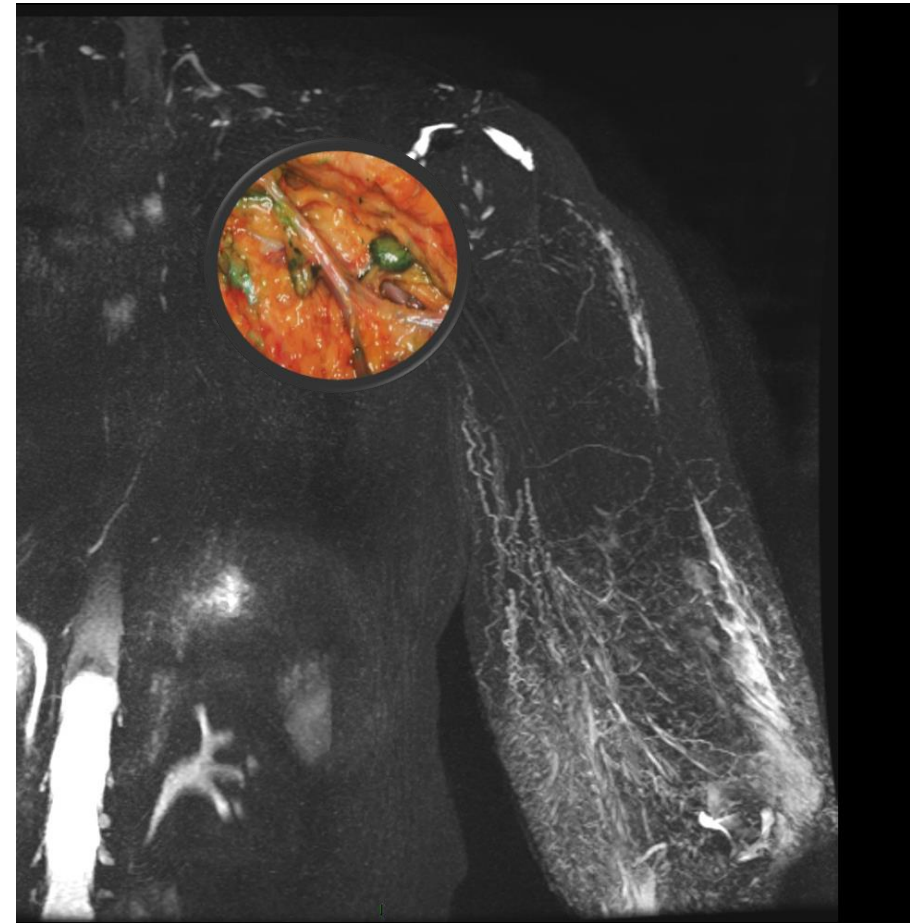
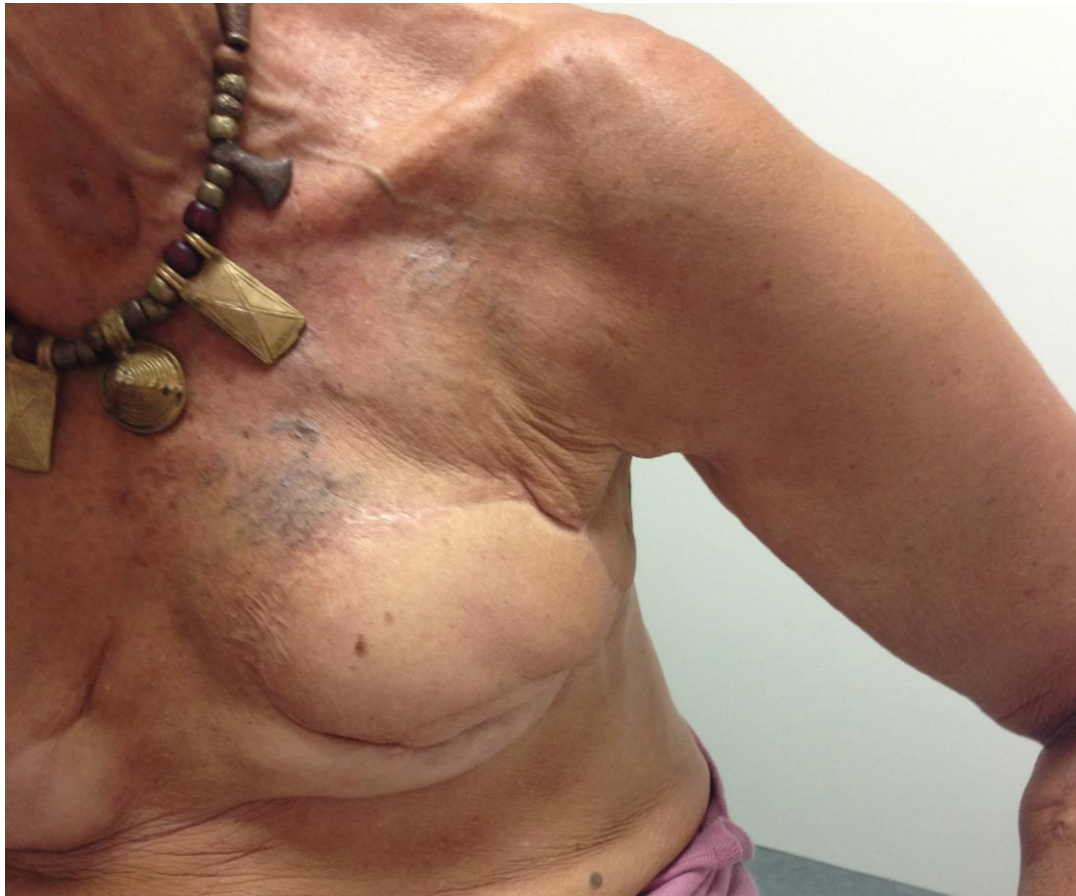Poor results if lymphatic vessels destroyed by chronic infections



TRUE STRATEGY

- LMRI MAPPING AND DEFECTS
- EXAMINATION OF THE FIBROSIS
- *IF STOP IN THE AXILLAIR REGION, REMOVAL OF THE FIBROSIS AND RECONSTRUCTION OF THE FREE FLAP*
- *IF DISTAL PROBLEM, FLAP CAN BE INSERTED AT THE ELBOW*
- *IF HUGE LYMPHOEDEMA, 2 FLAPS (AXILLAIR AND ELBOW)*
- *COMBINATION WITH LIPOSCULPTURE IN FAT DEPOSITS*

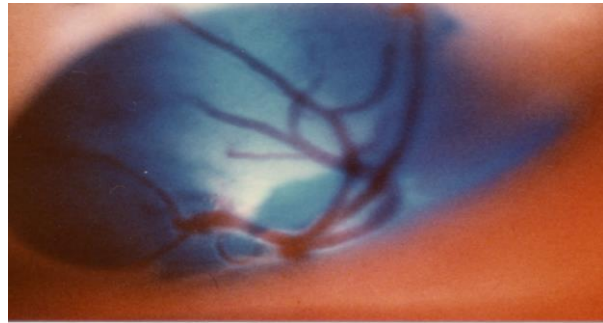
**RECONSTRUCTION OF THE AXILLAR
REGION SEEMS MORE LOGIC
BY LYMPHNODE FLAP(LIVING NODES)**



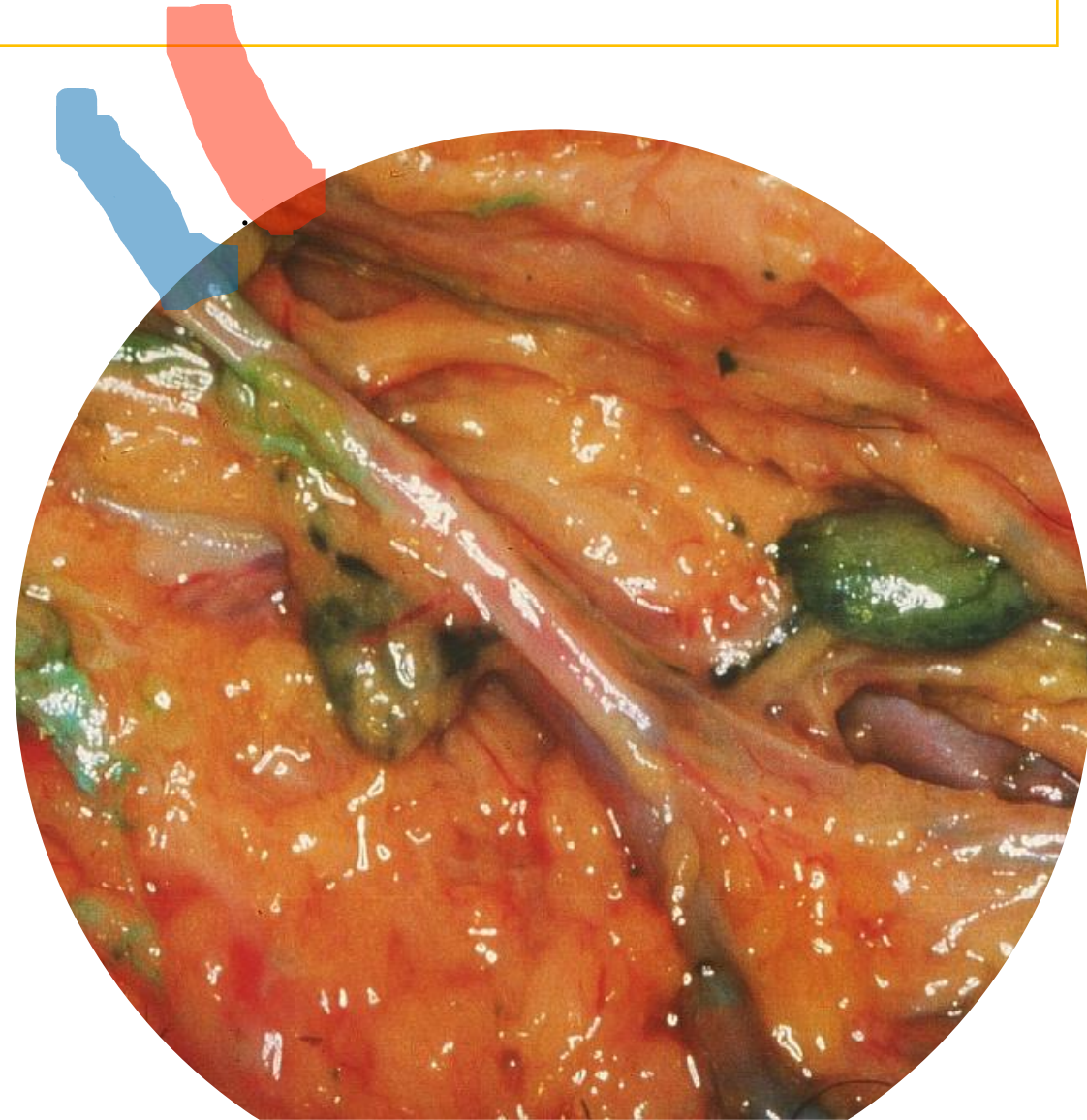
CONCEPT:

TRUE RECONSTRUCTION

- LIVING TRANSPLANT **BRIDGING** AFTER REMOVAL OF THE FIBROSIS
- TRANSPLANTATION OF LYMPHNODES = **PUMPS**
- EACH NODE IS LIKE **MULTIPLE LV ANASTOMOSIS**



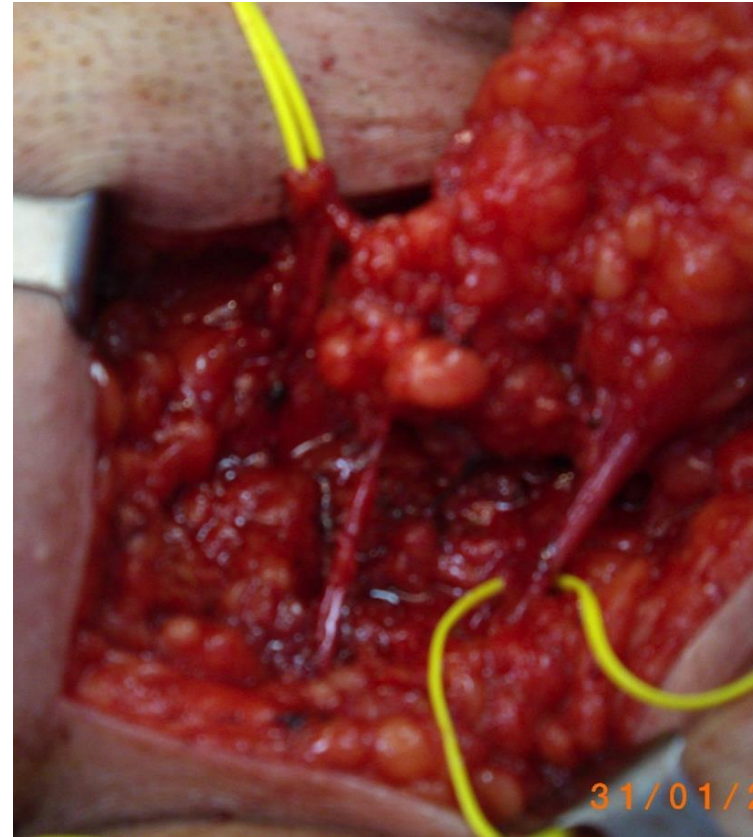
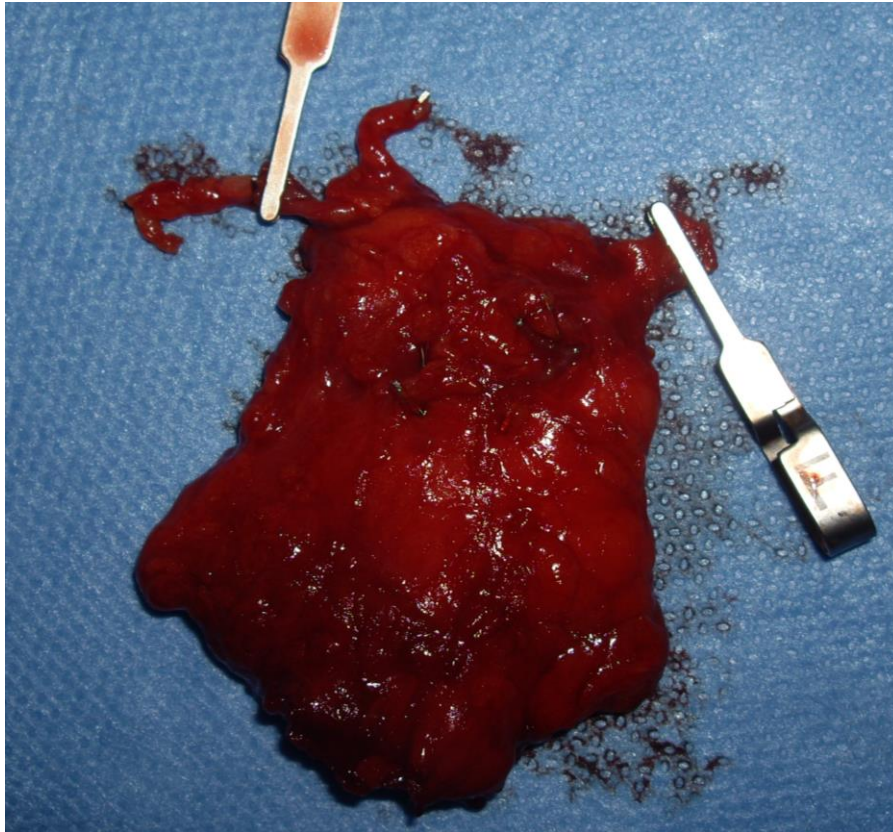
- NEOGENESIS OF THE LYMPHATIC VESSEL (**VGEFC** IN NODES AND FAT AROUND THEM)



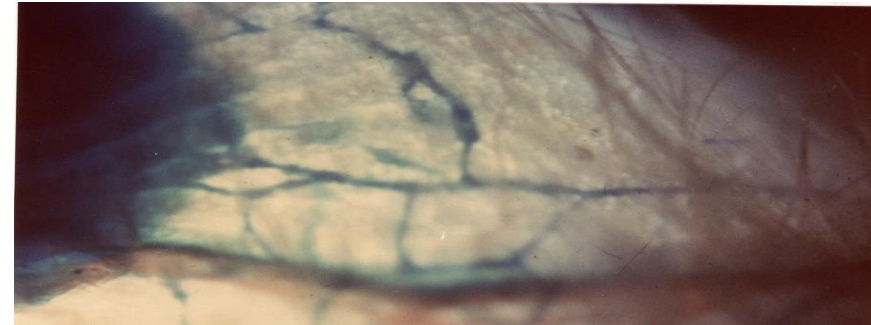
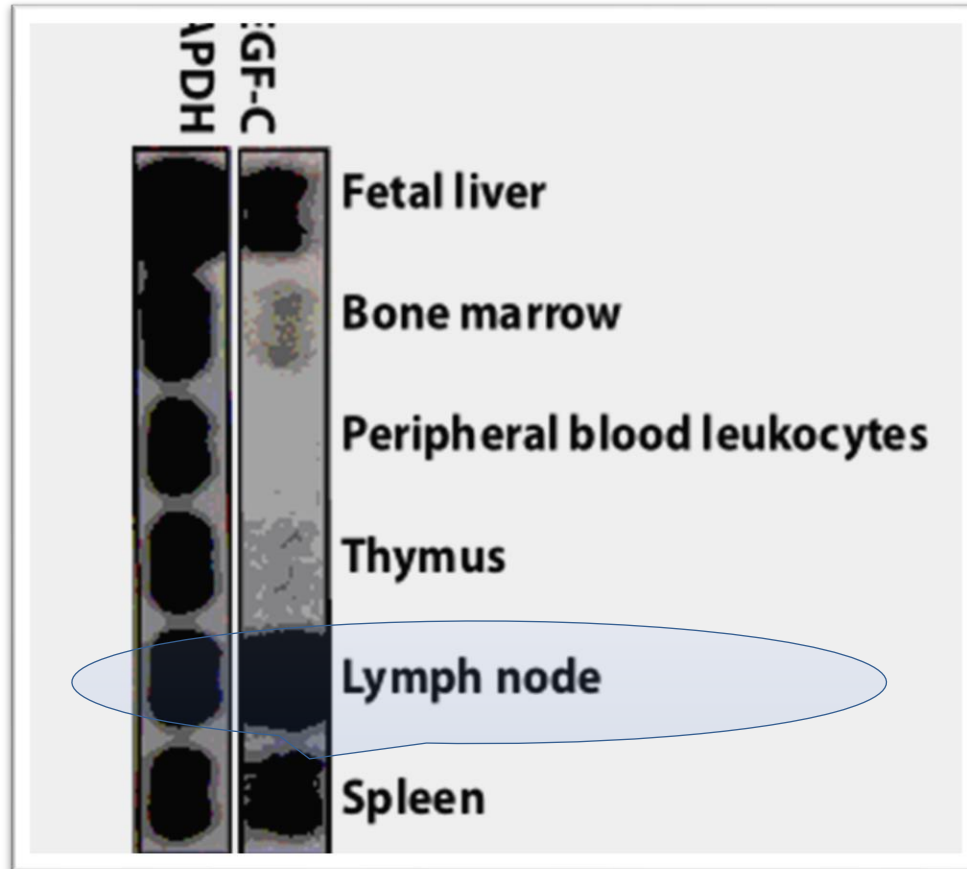
CONCEPT



- FREE FLAP CONTAINING NODES (VGEFC) AND SPECIAL FAT AROUND THE NODES (CYTOKINES)

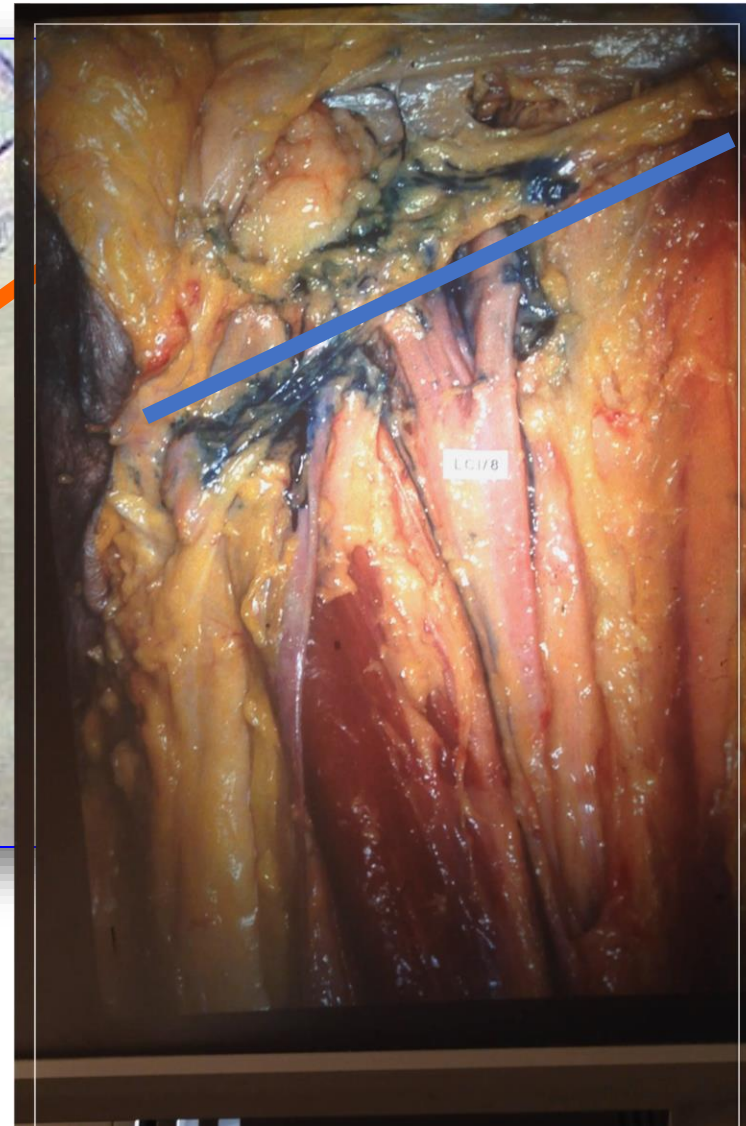
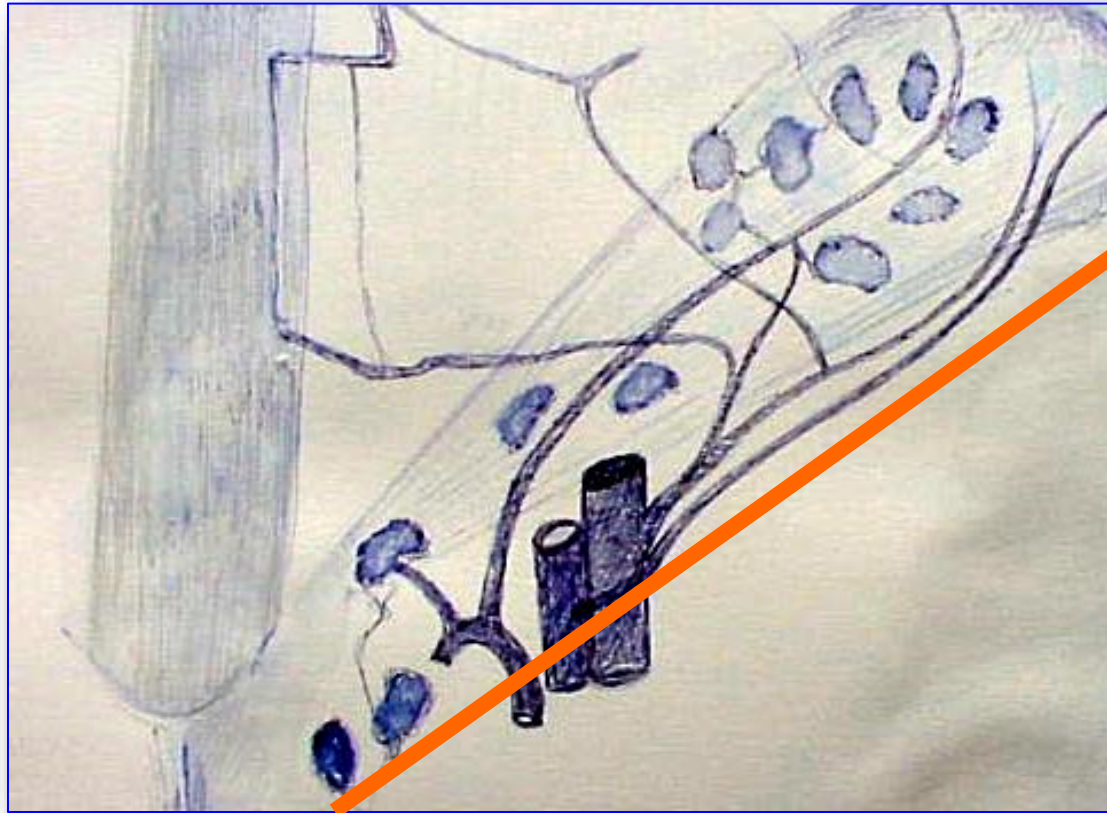


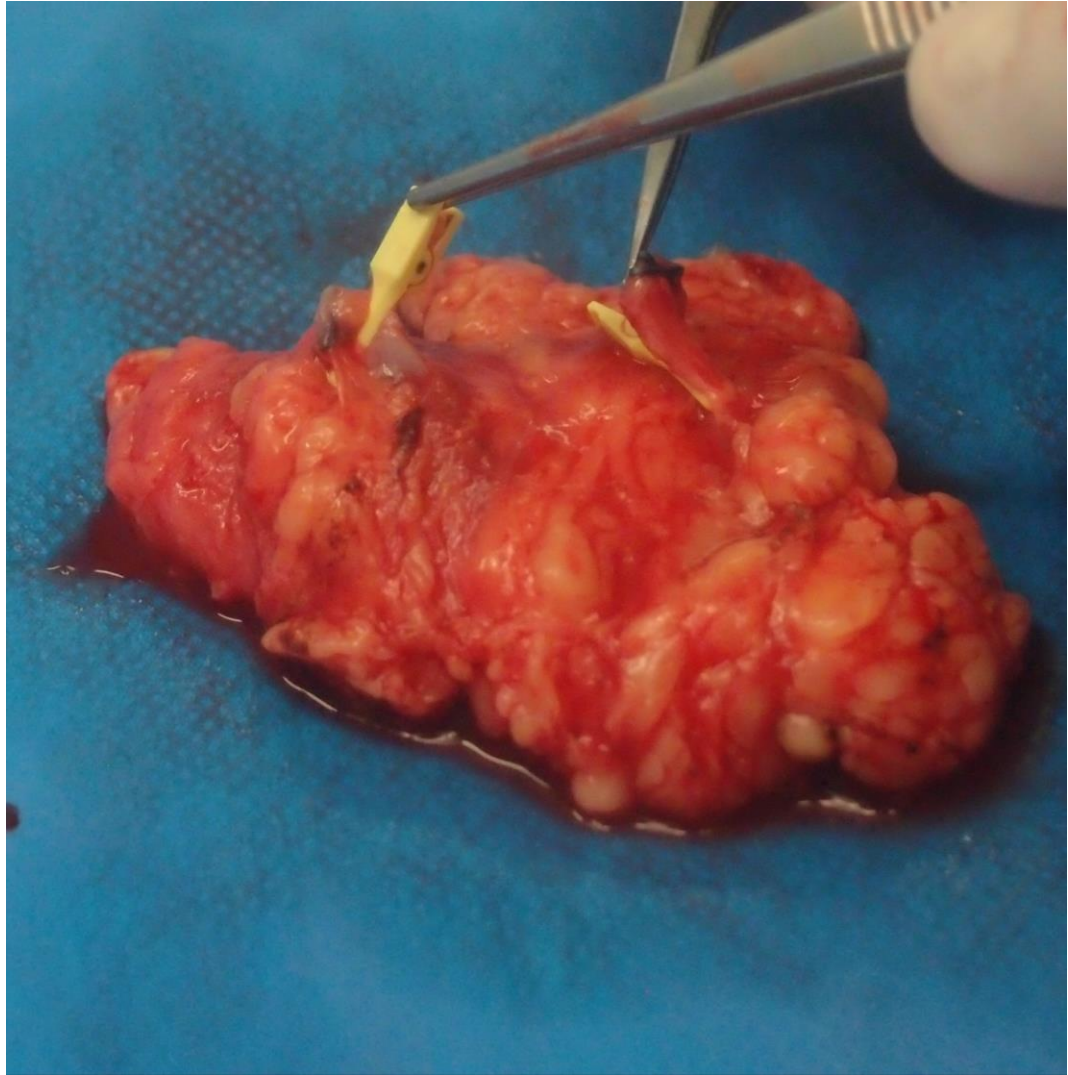
REGENERATION OF LYMPHATIC VESSELS



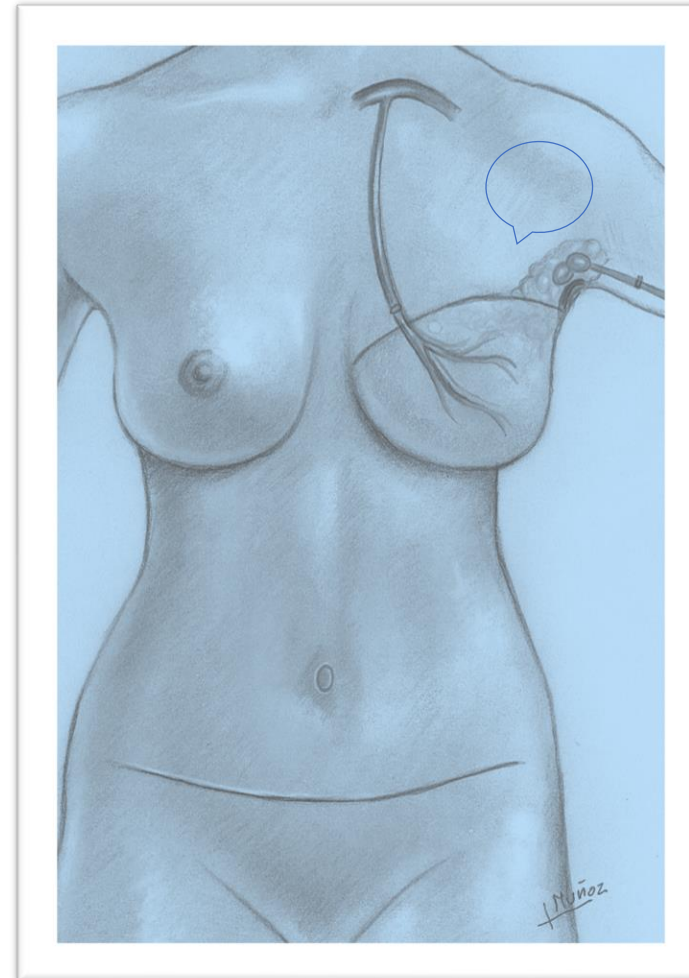
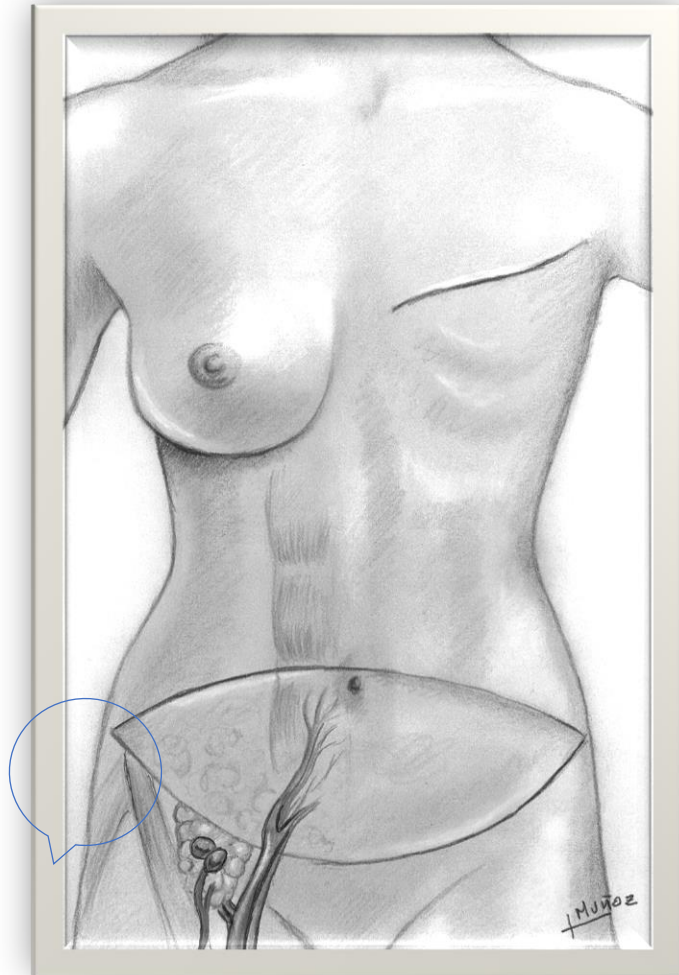
VEGF IN NODES
CITOKINES IN THE FAT

INF LIMIT=EMERGENCE OF THE CIRCONFLEX SUP.ILIAC VESSELS.DO NOT GO LOWER!!!****

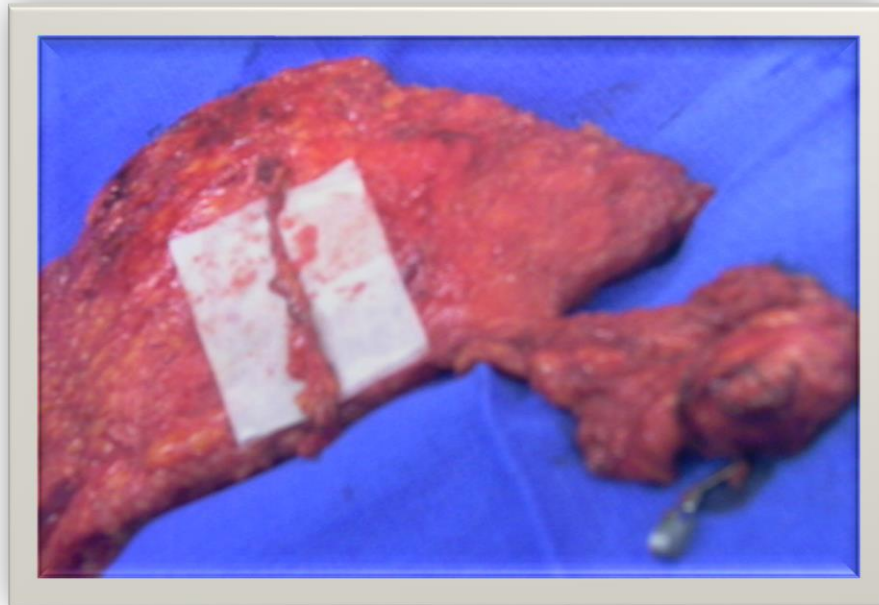
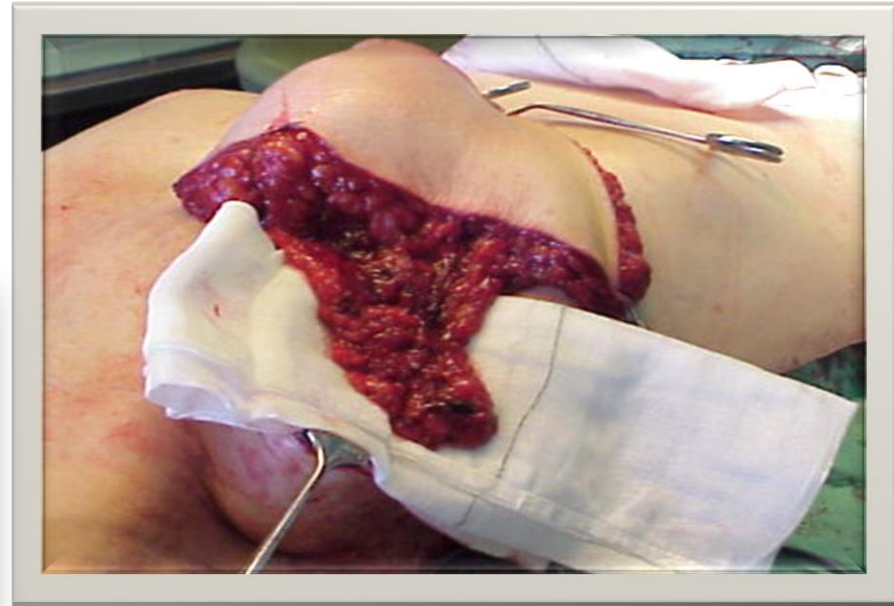
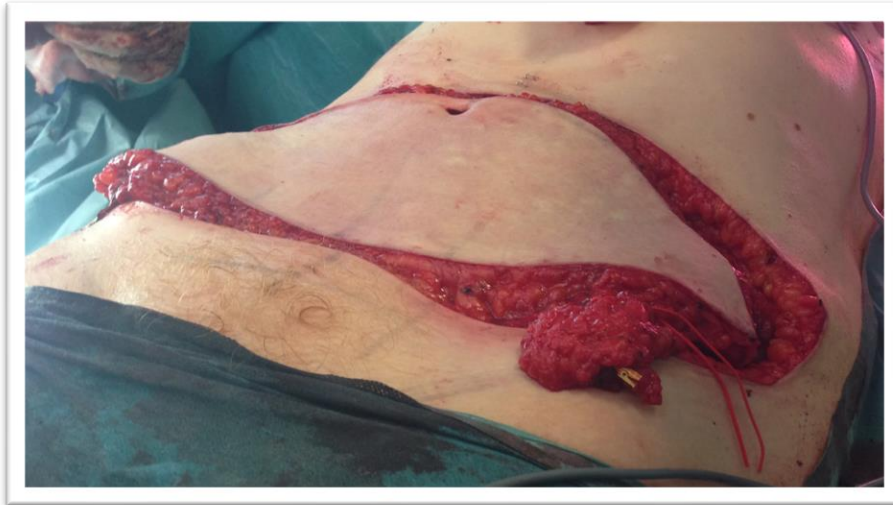


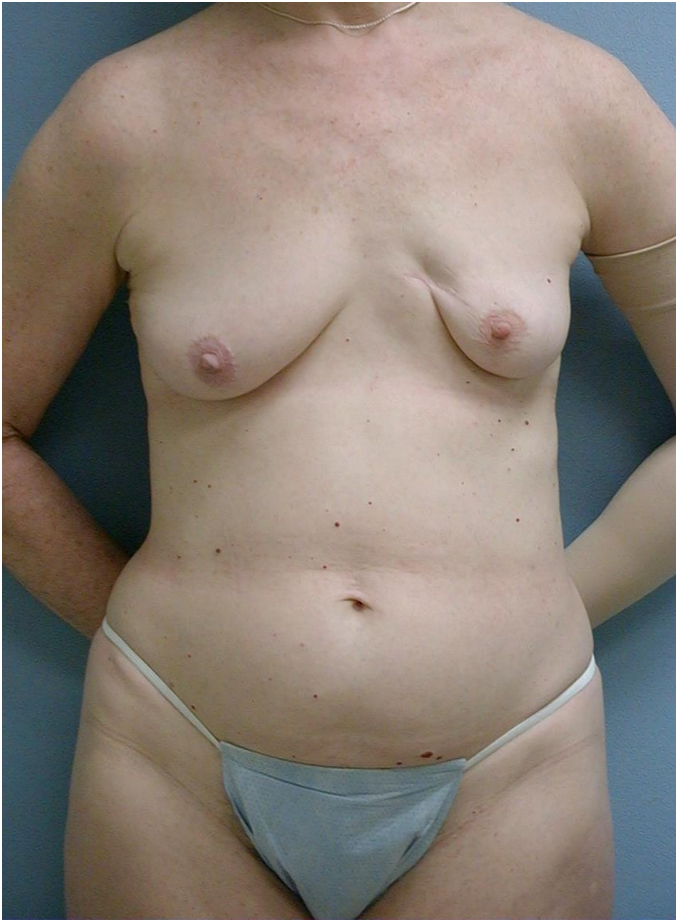IF THE BREAST MUST BE RECONSTRUCTED
DIEP :NODES INCLUDED IN THE ABDOMINAL FLAP



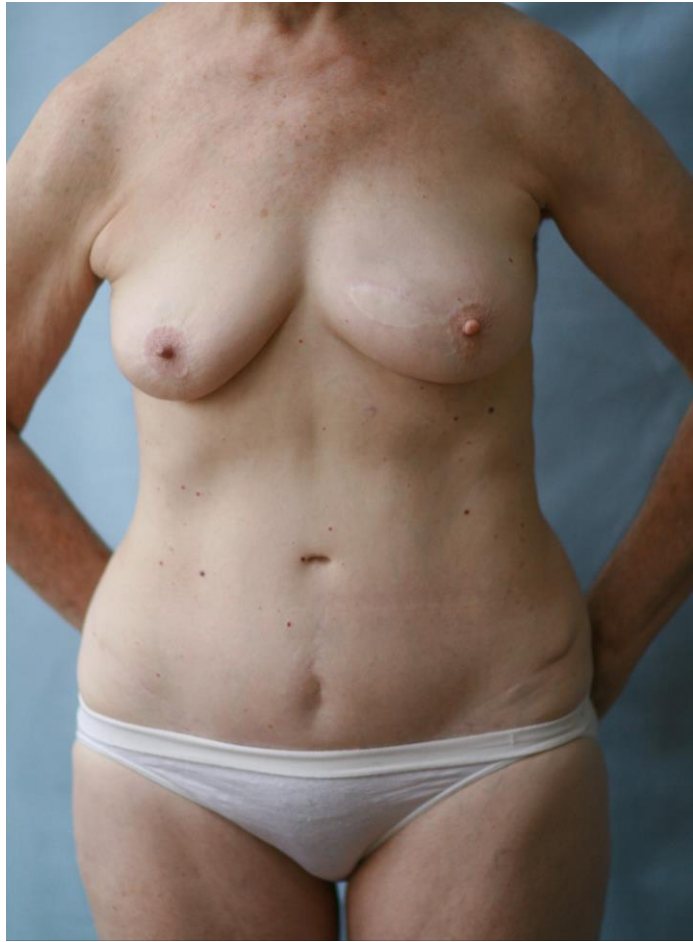DIEP INCLUDING LYMPHNODES FLAP



PREOP AND

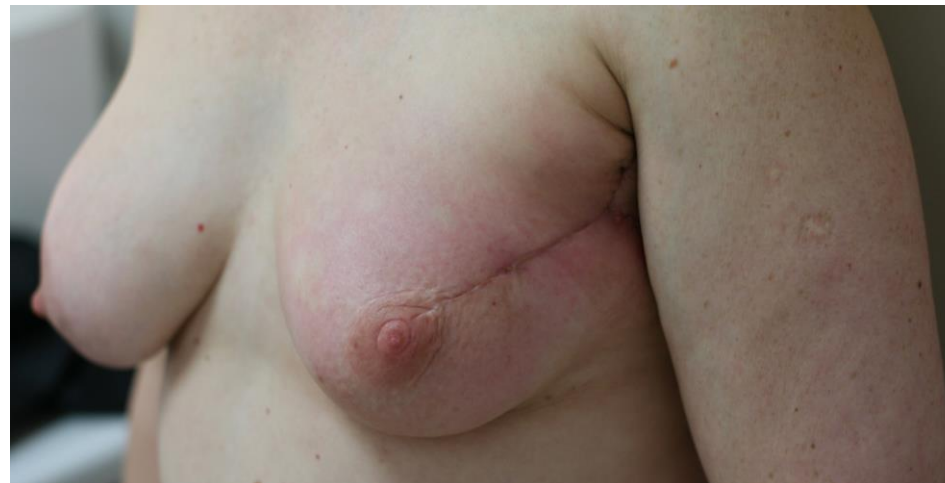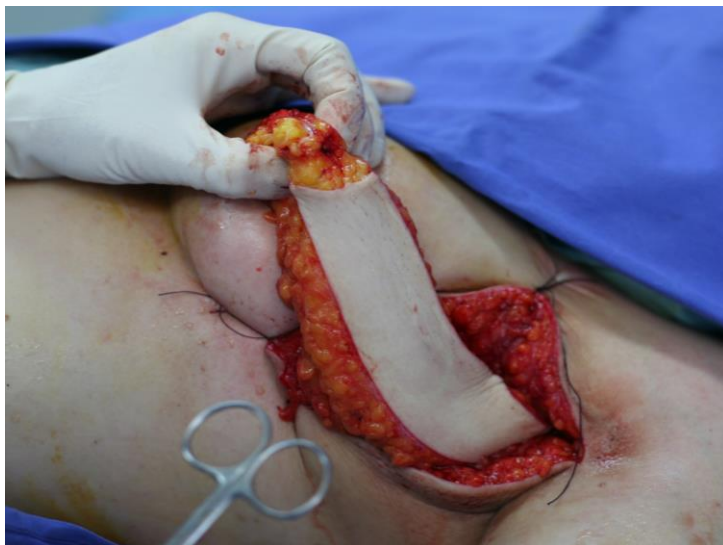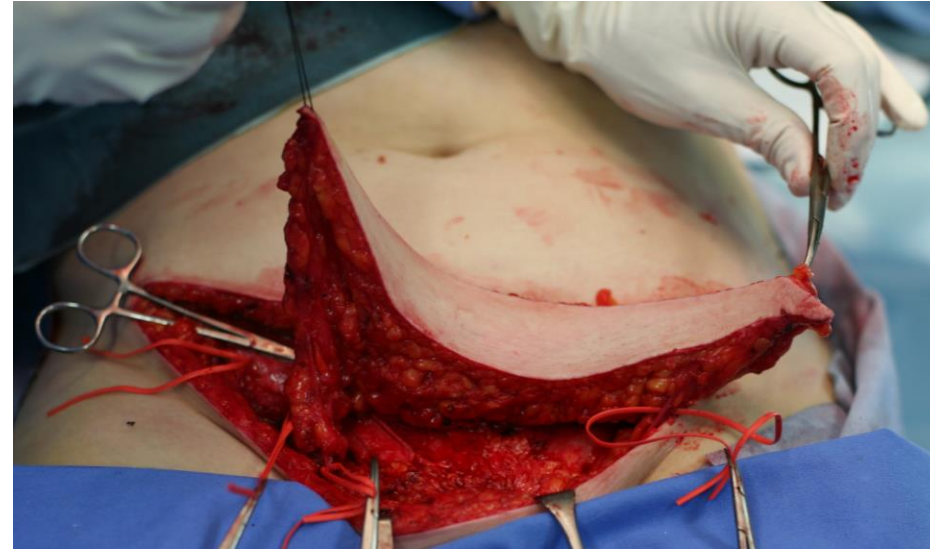


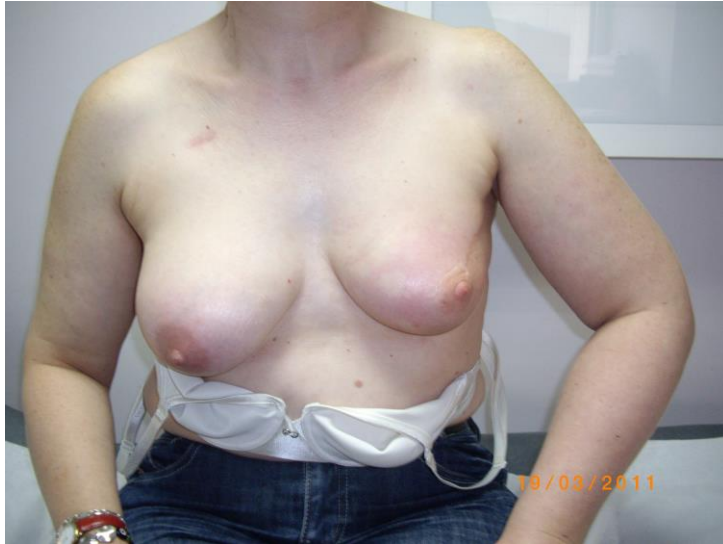6 M AFTER SURGERY

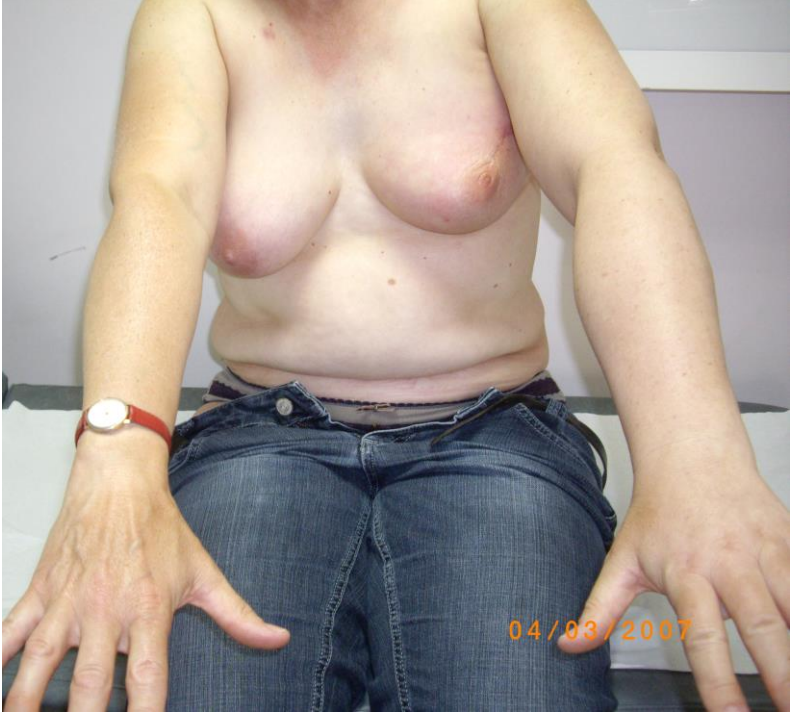

« ELEGANCE »

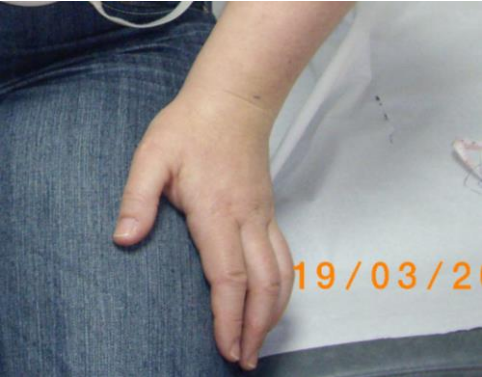FILLING THE BREAST PLUS TREATMENT OF LYMPHOEDEMA



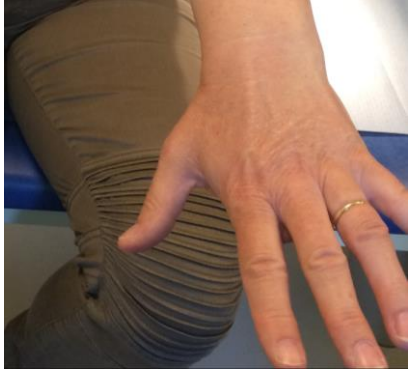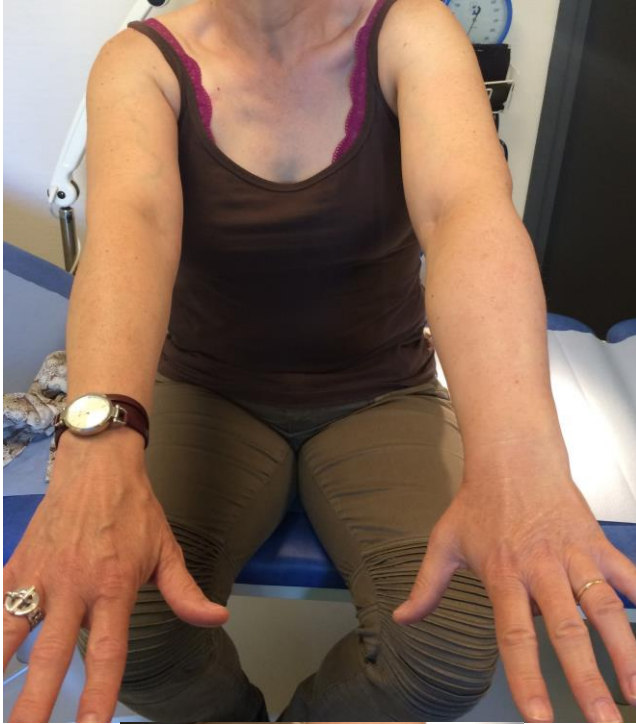**PREOP EXTREM FIBROTIC HAND
AND 3 YEARS LATER**



Fibrosis++++

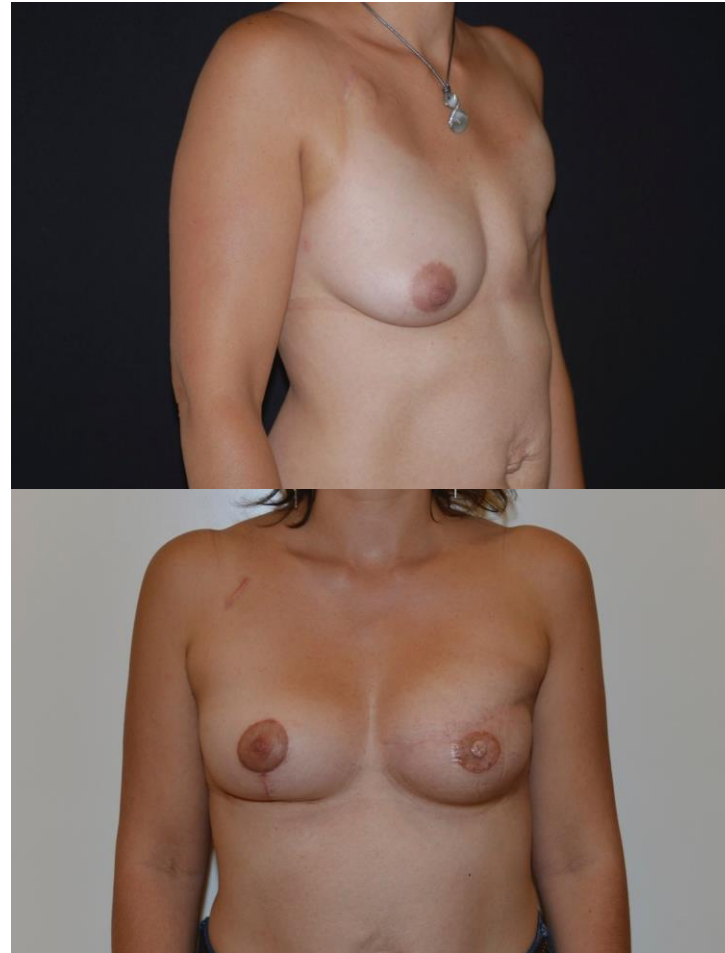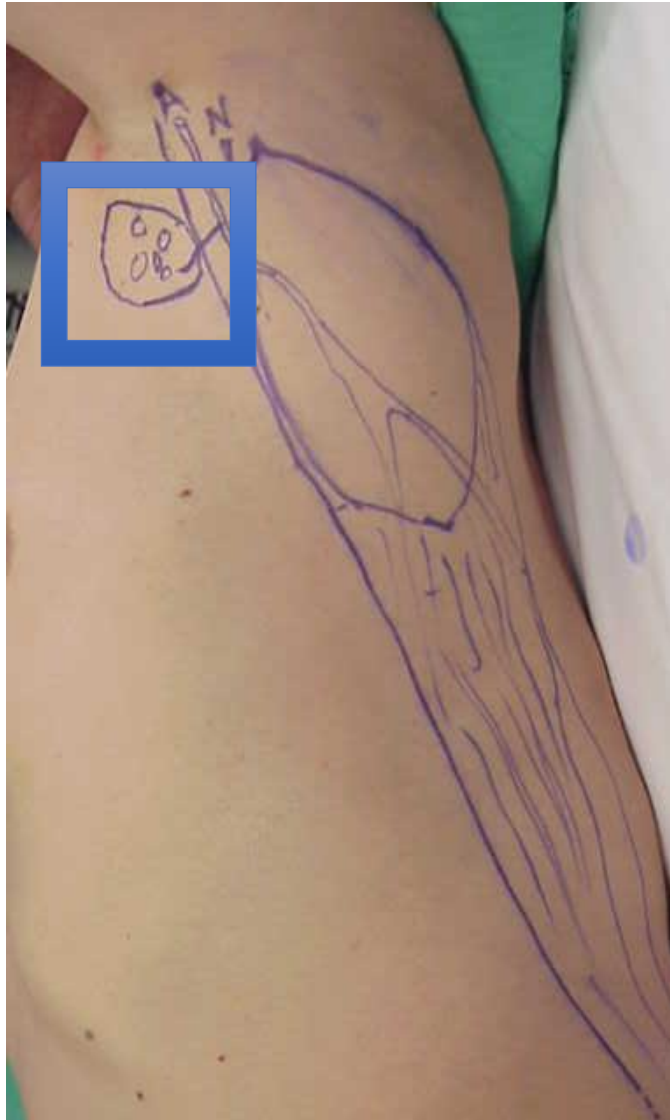


**AFTER 1 YEAR,NO MORE PHYSICAL
TREATMENT**

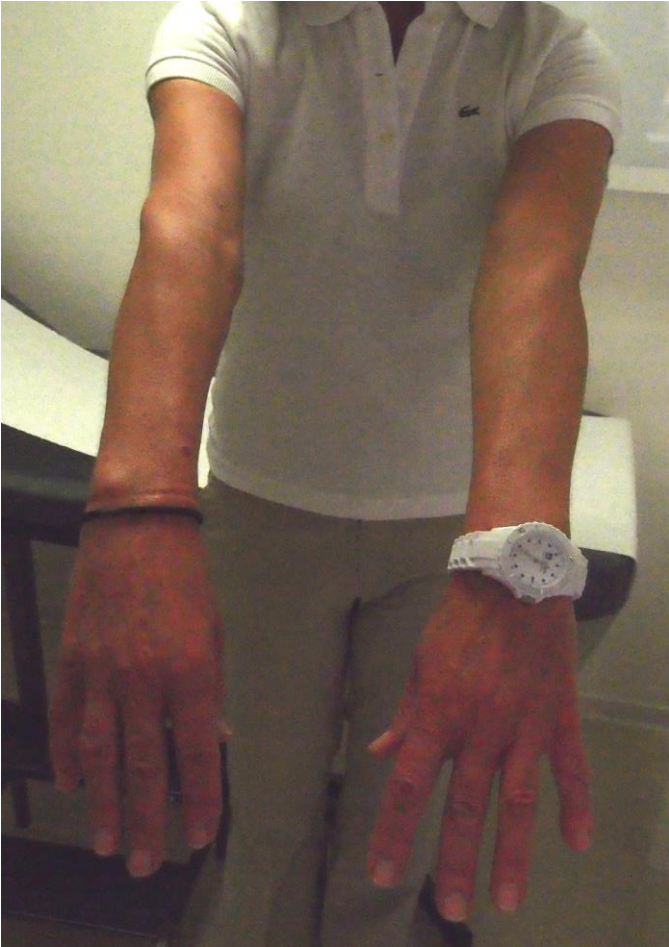
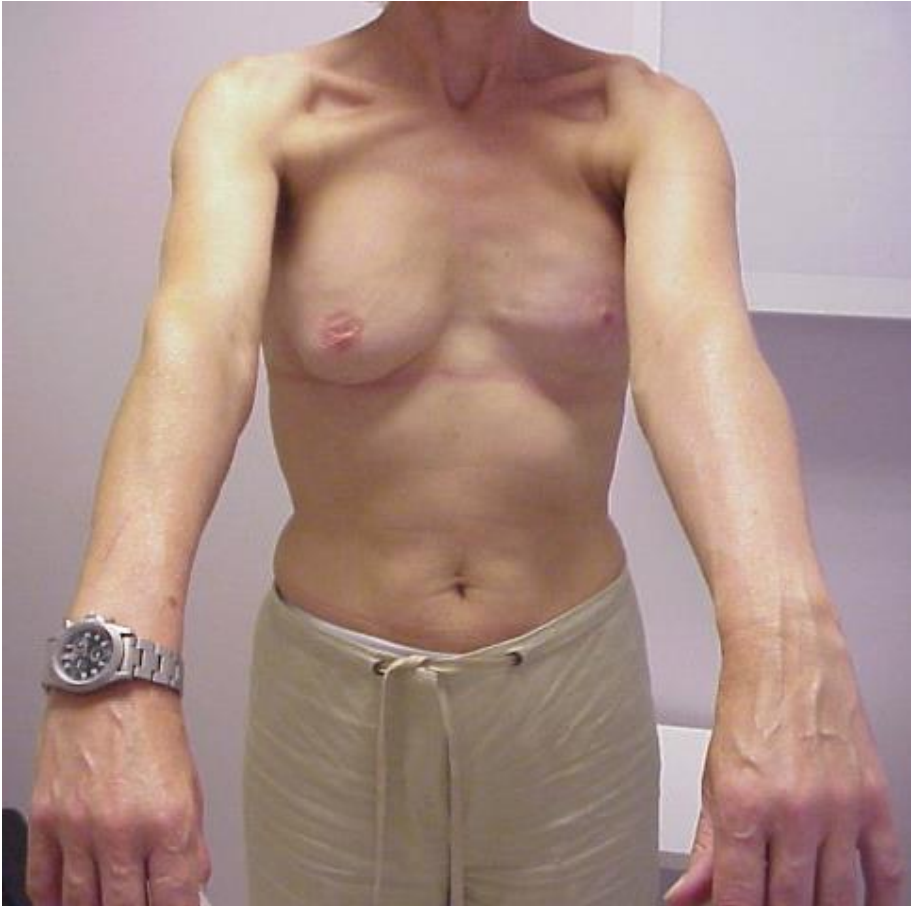
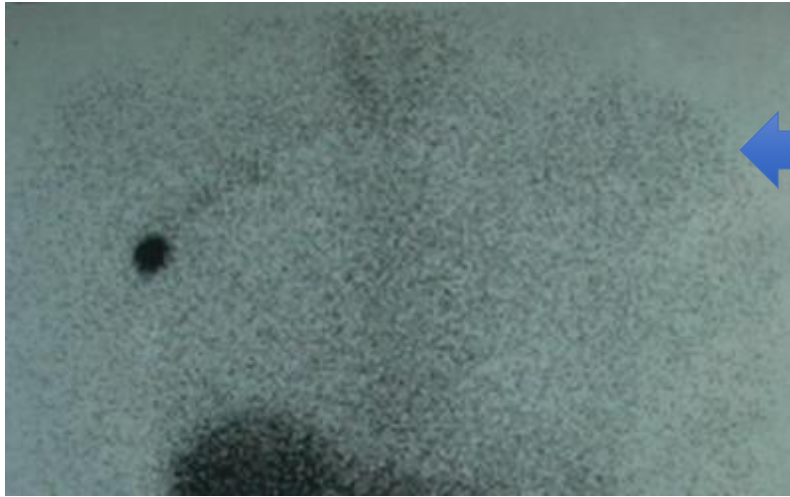
LYMPHNODES CAN BE ADDED TO ANY KIND OF FLAP FOR IMMEDIATE RECONSTRUCTION:

1. DORSALIS FLAP



PREOP AND 10Y AFTER ALNT WITHOUT ANY TREATMENT

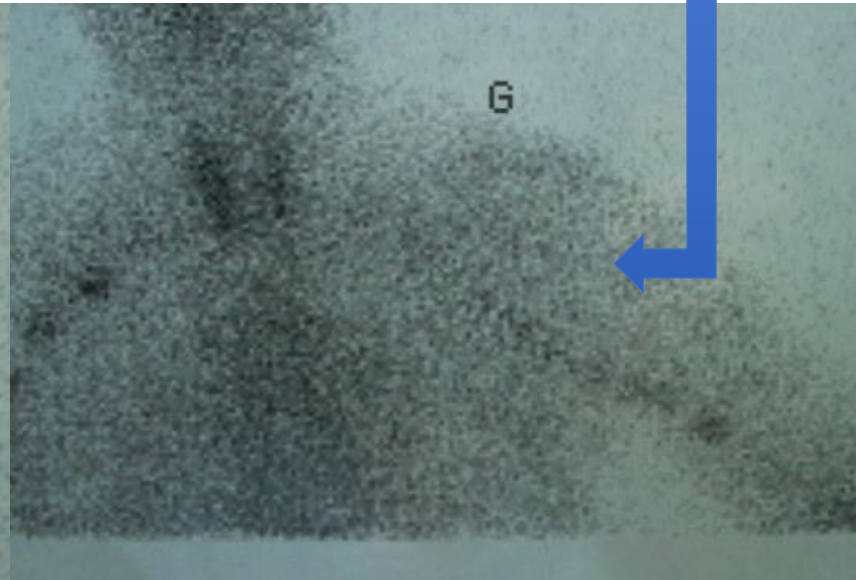





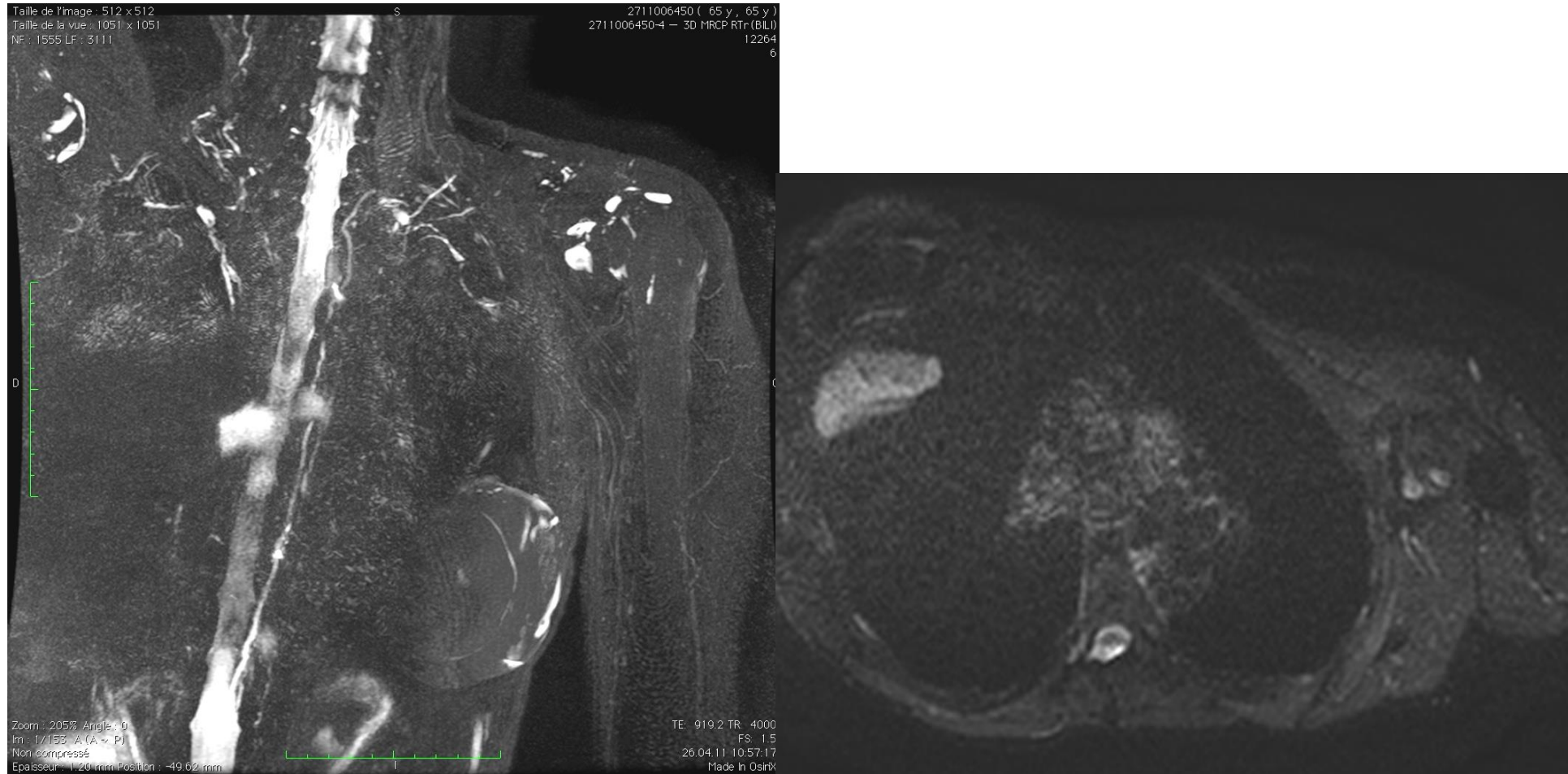
PREOP

1 YEAR P.OP

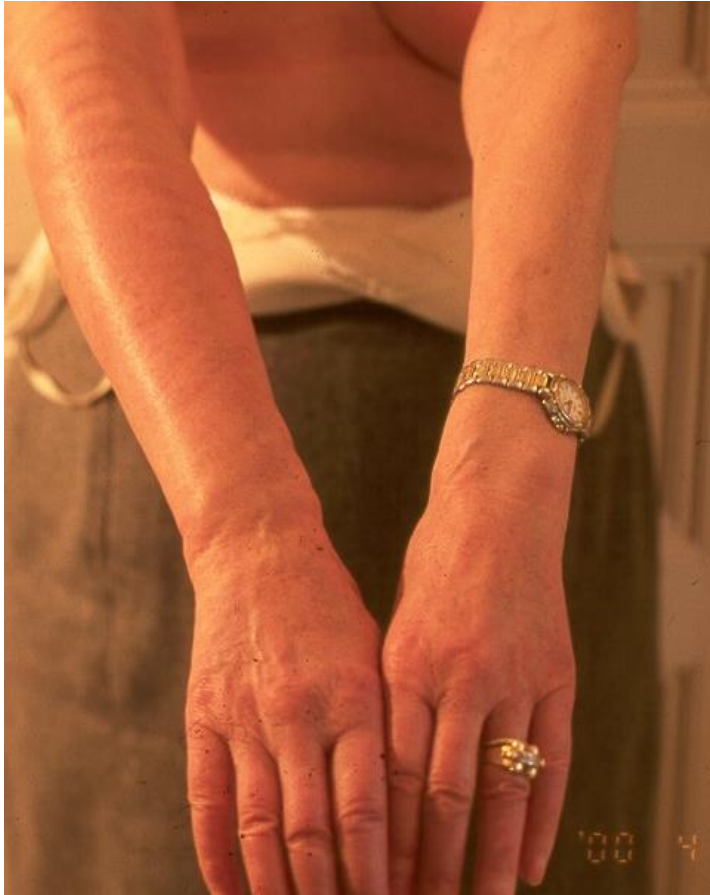5 ANS P.OP



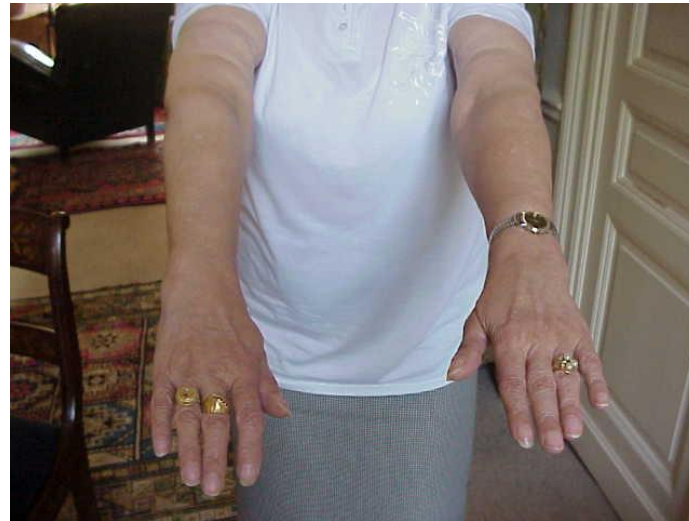8 YEARS AFTER ALNT: NORMAL SITUATION



PRE OP



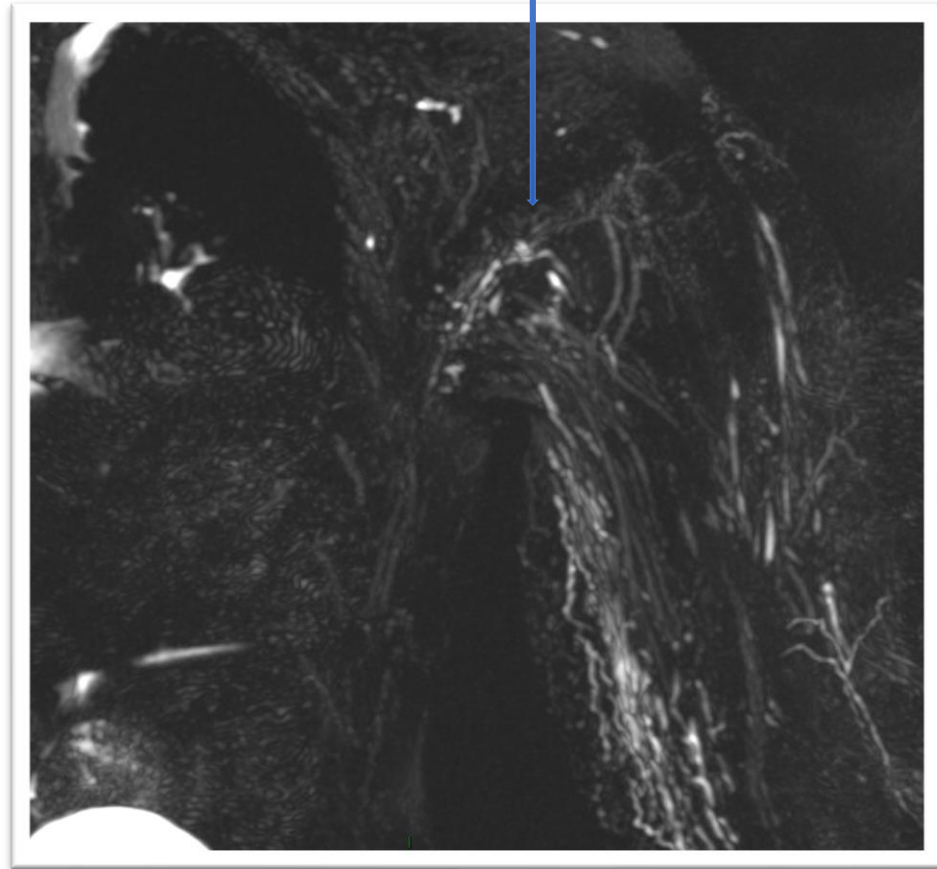
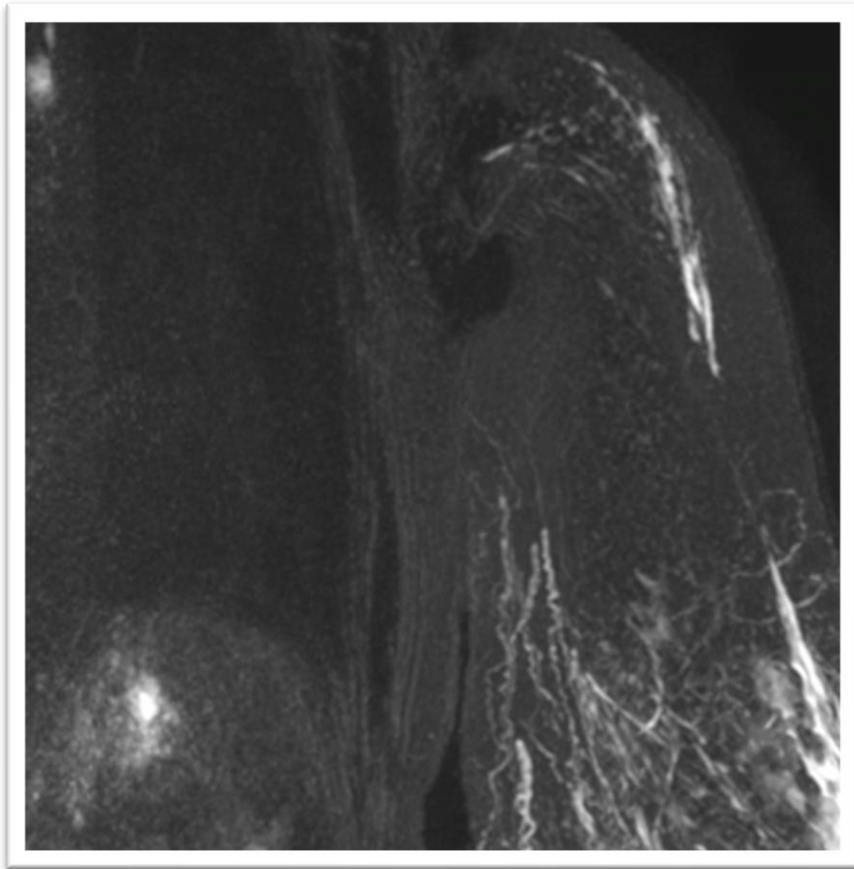
2 Y P.O.

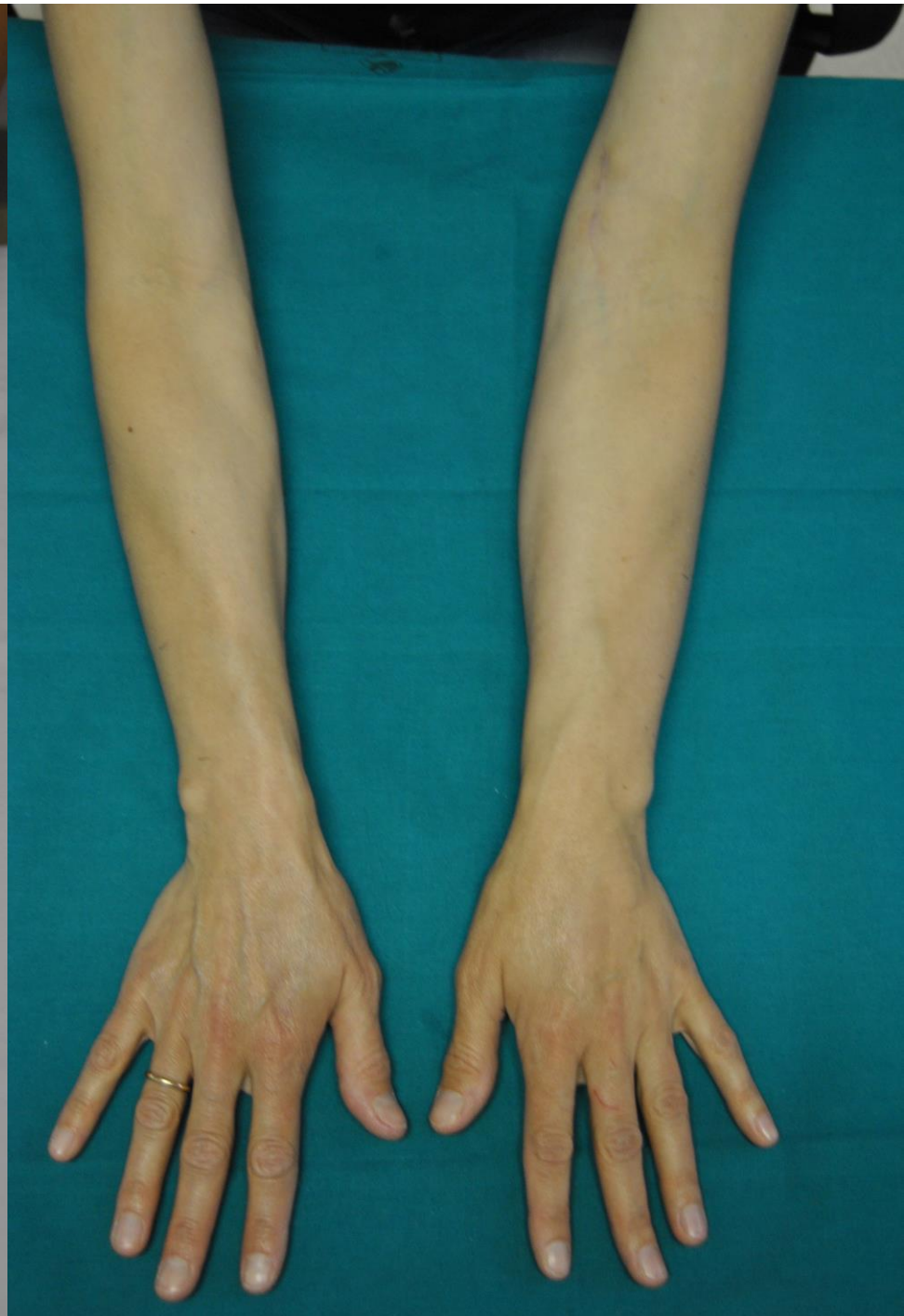
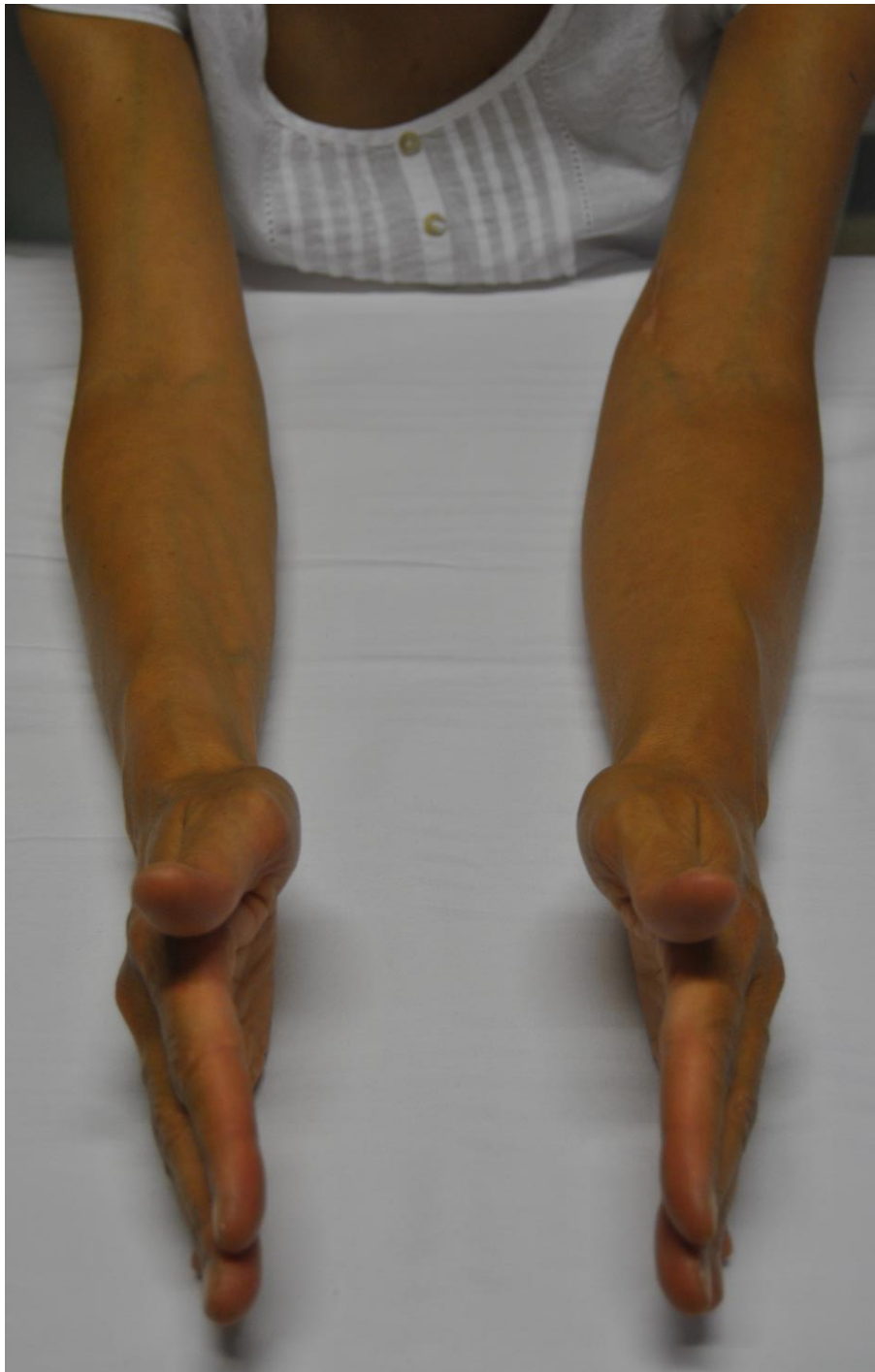
PREOP.
ALNT

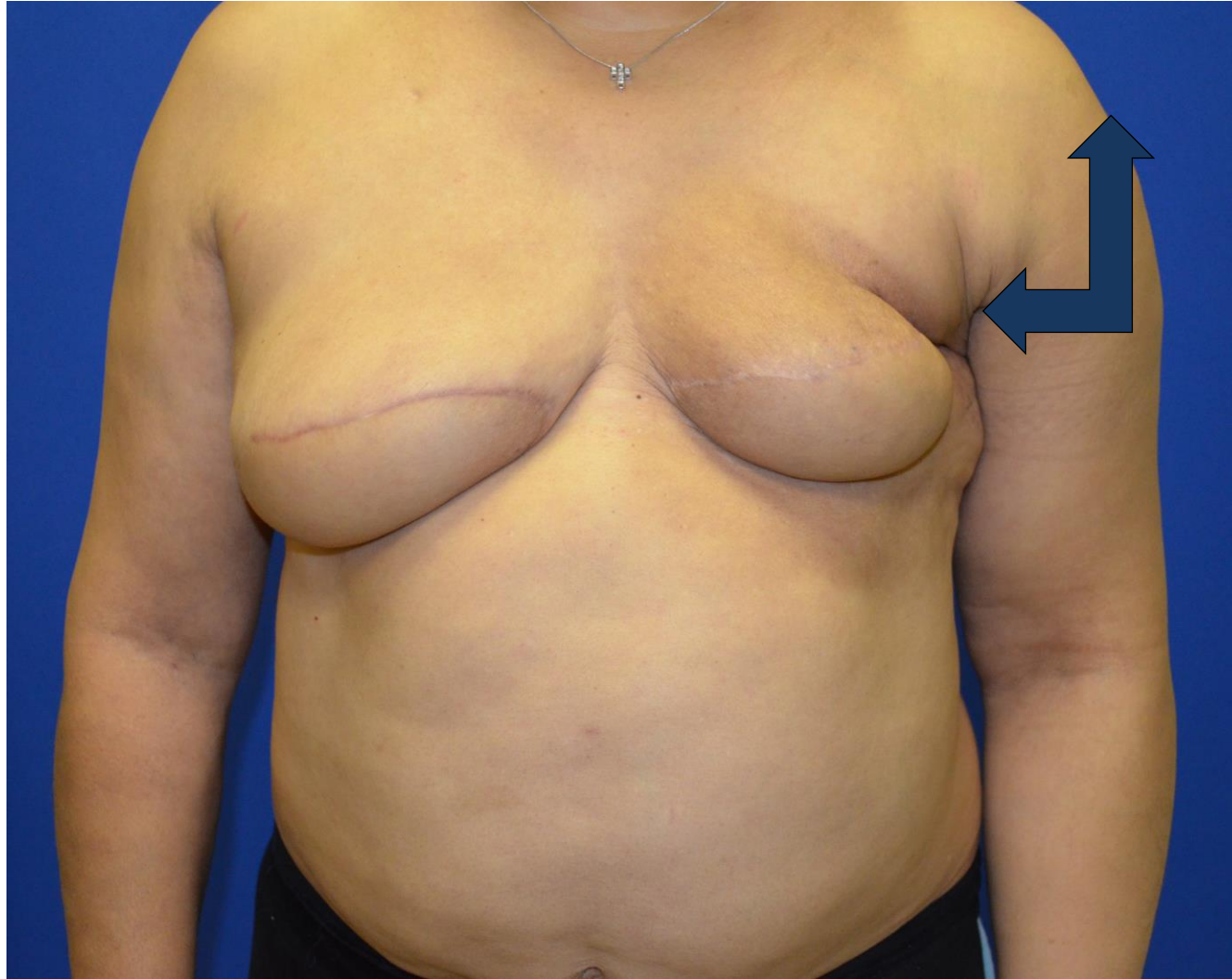
AND

1 YEAR AFTER

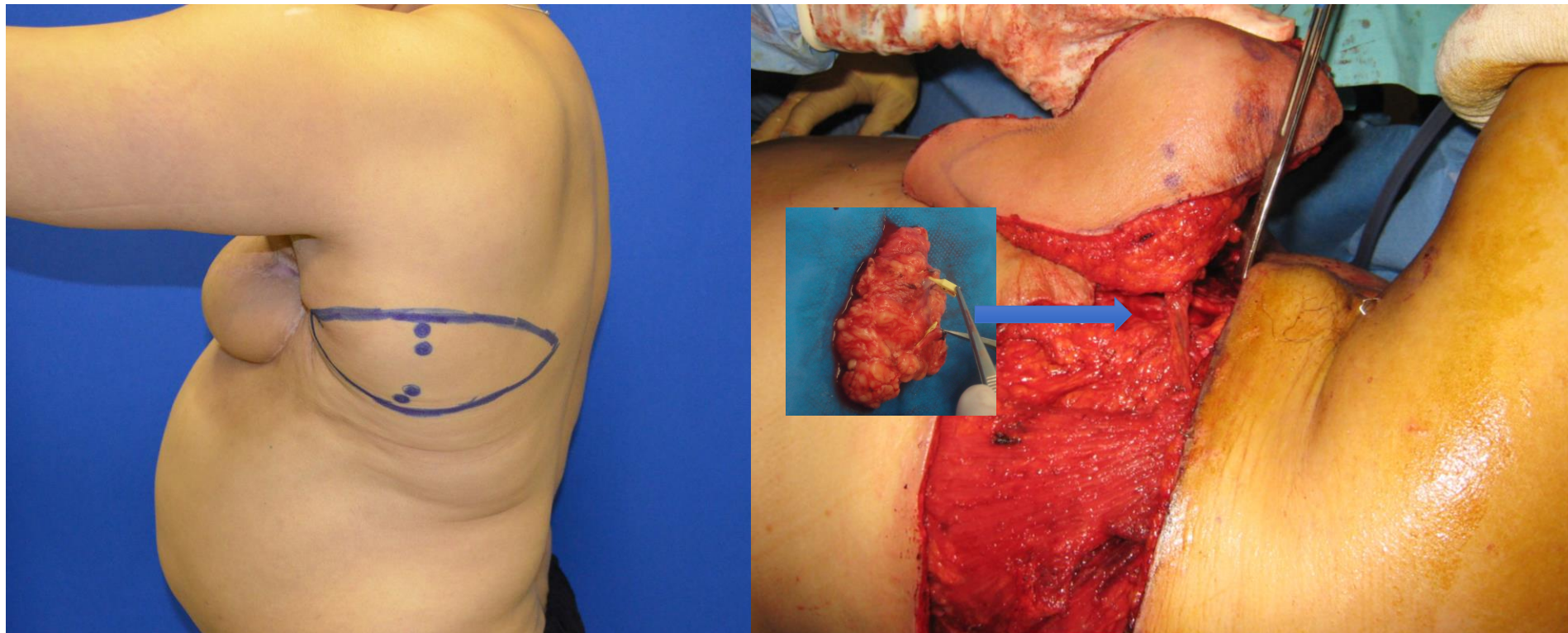


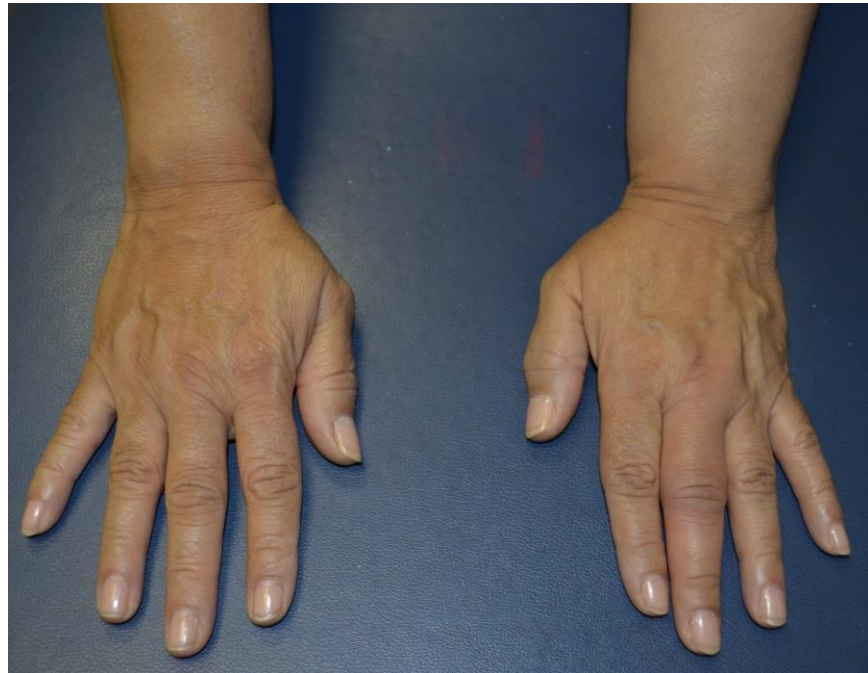
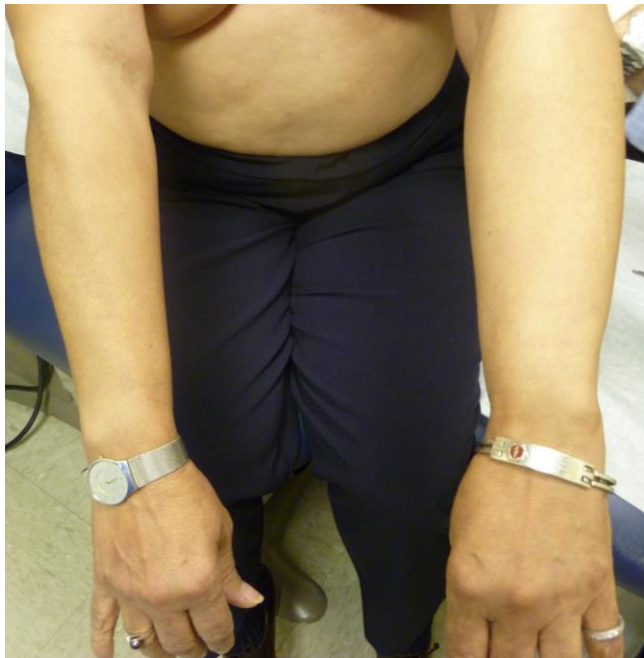
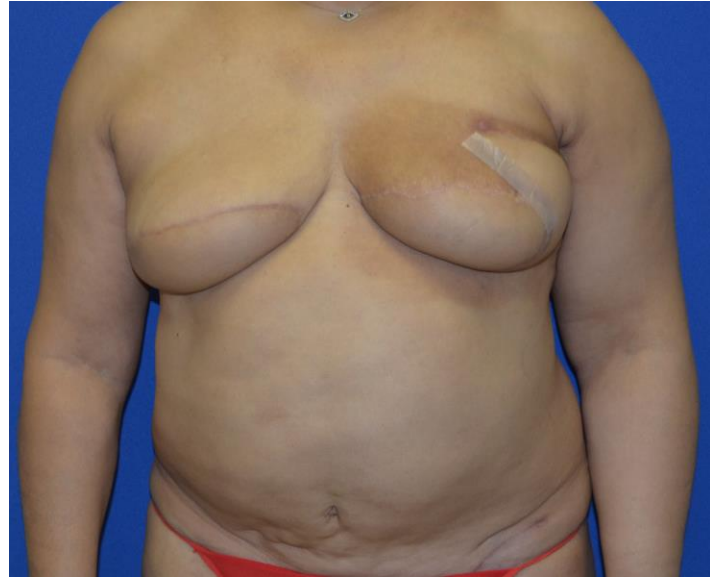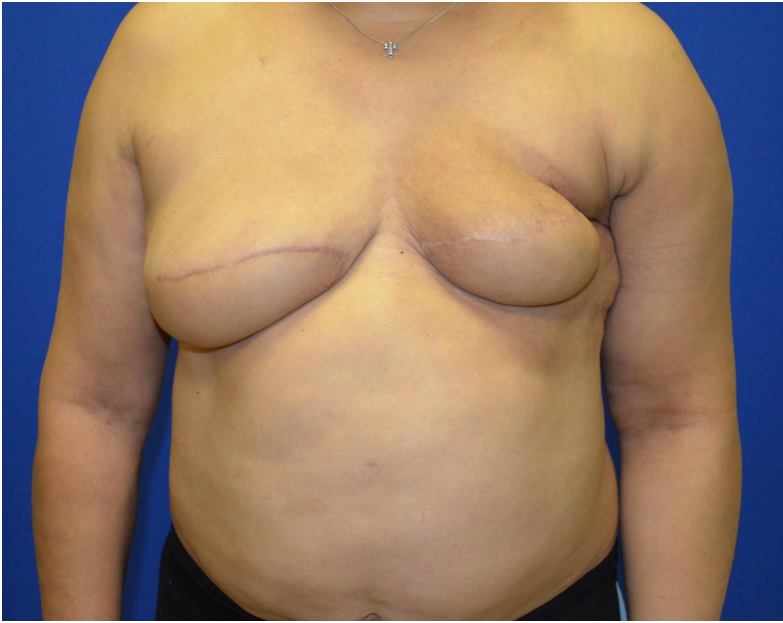**AFTER BILAT DIEP, HOW TO TREAT LYPHOEDEMA AND
CHRONIC INFECTION?**

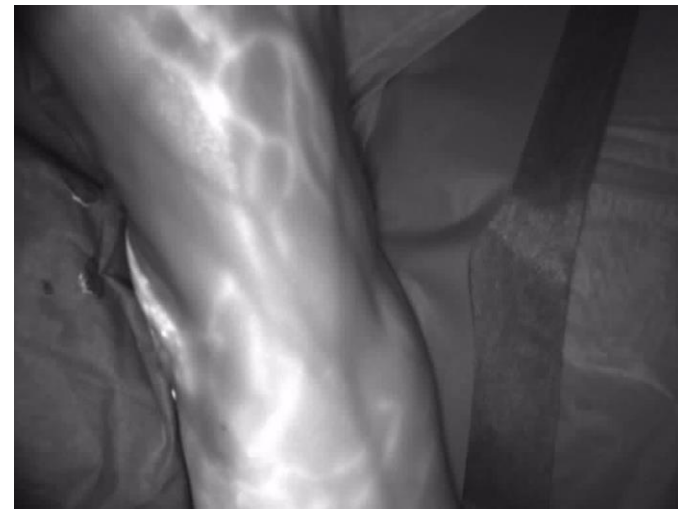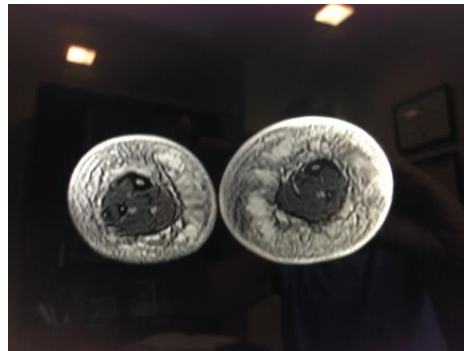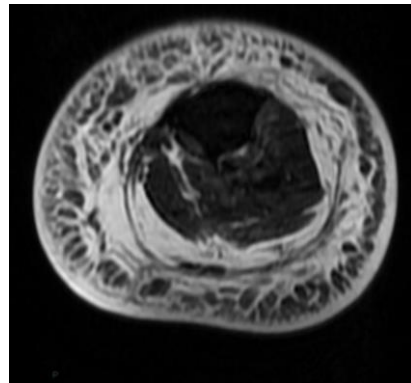
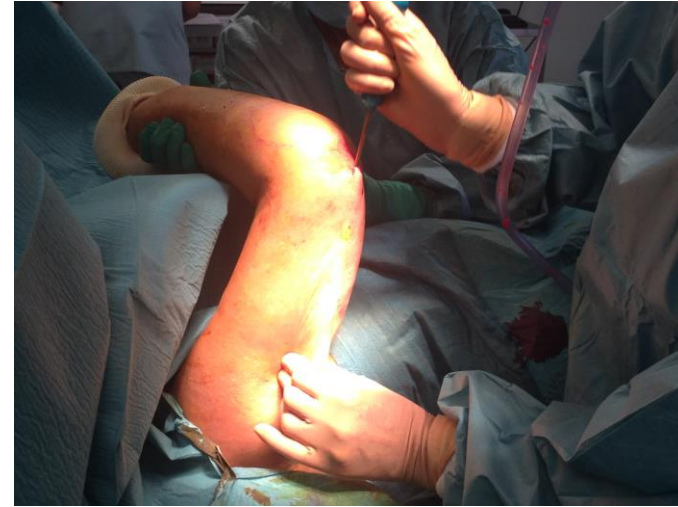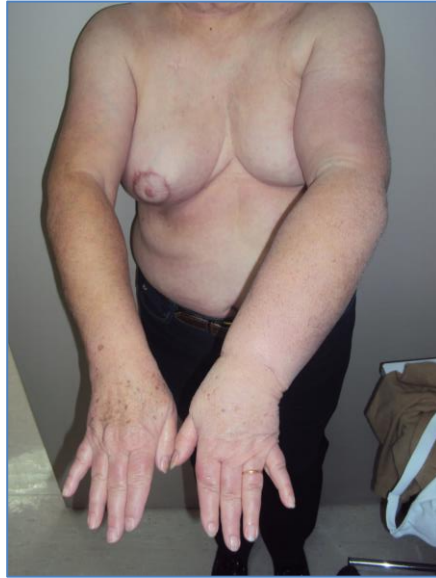


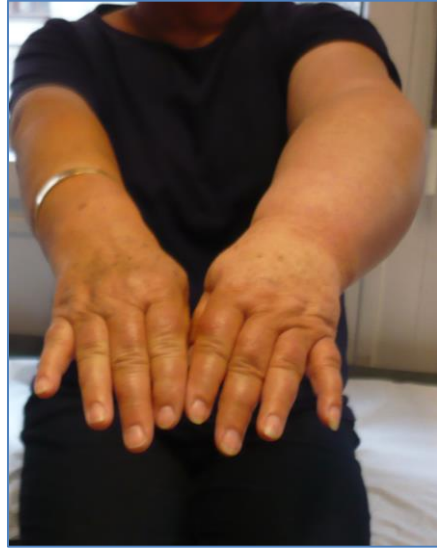TDAP WITH ADDED WITH FREE LYMPHNODES FLAP

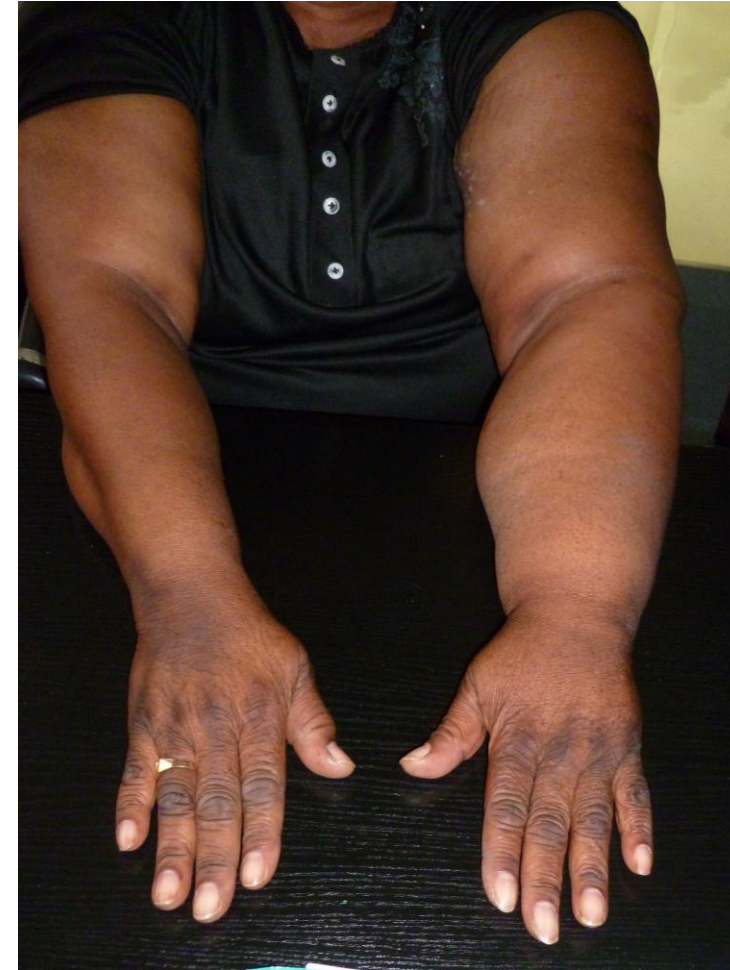
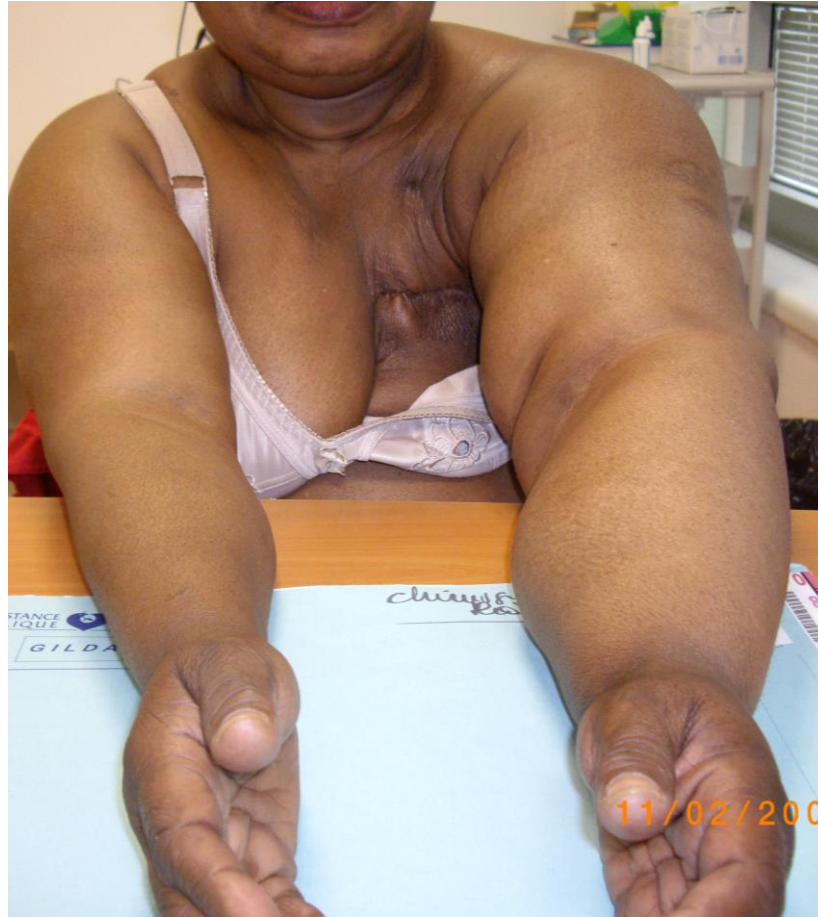




ADDITIONAL EXTERNAL MINI LIPOSCULPTURE 1 YEAR AFTER LYMPH NODE TRANSPLANTATION, USING PEROP SPY



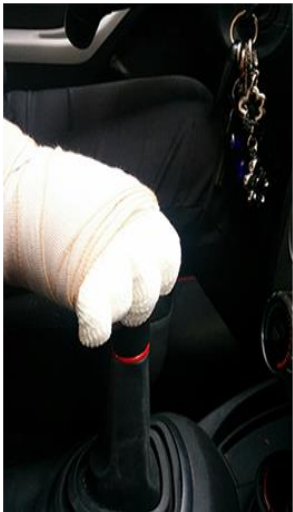
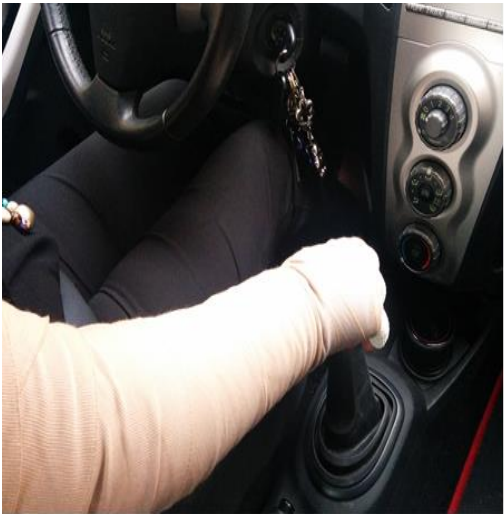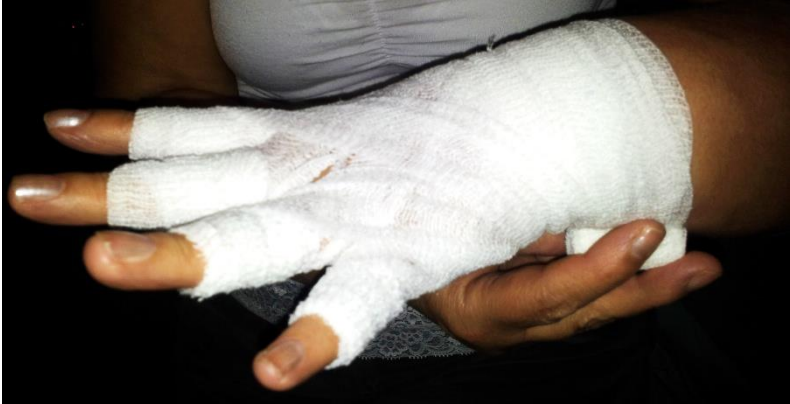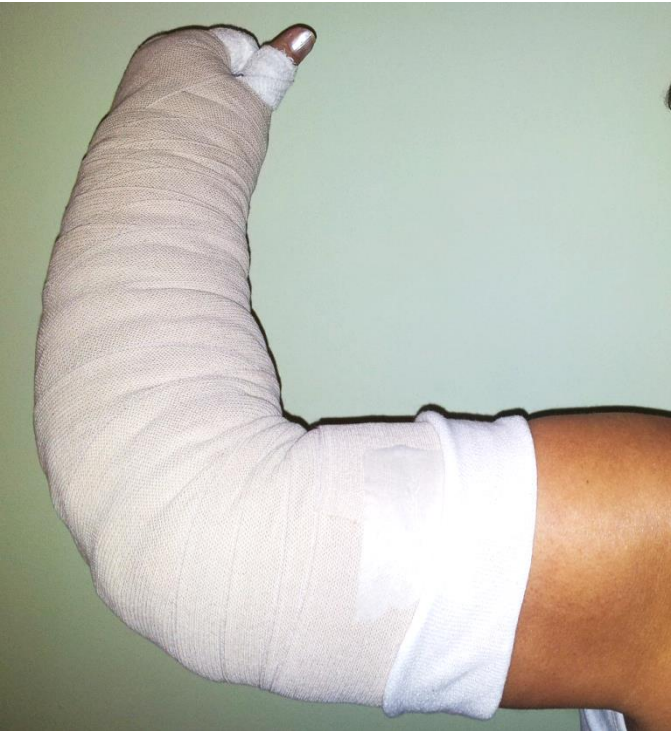LARGE LYMPHOEDEMA: LYMPHNODE TRANSFER COMBINED WITH LYMPHNODE TRANSFER



Manual drainages , bandaging.

3X/week for 3 months post op.,no sleeves after ALNT

Auto-bandage

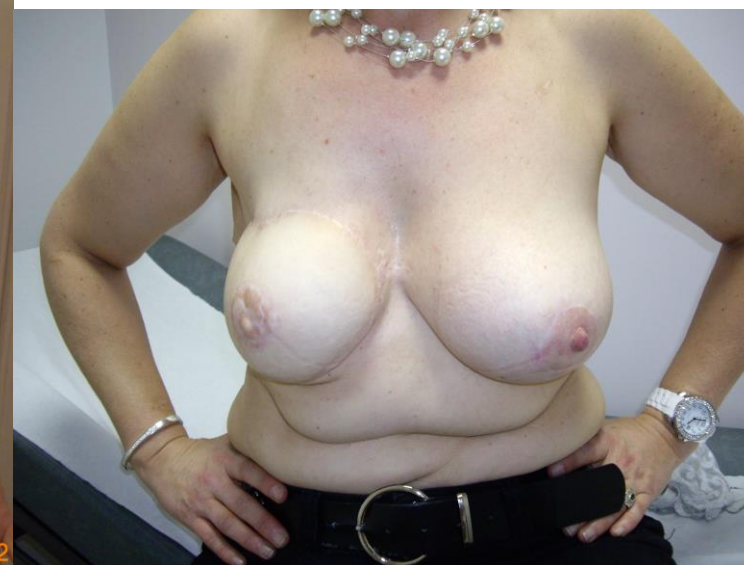
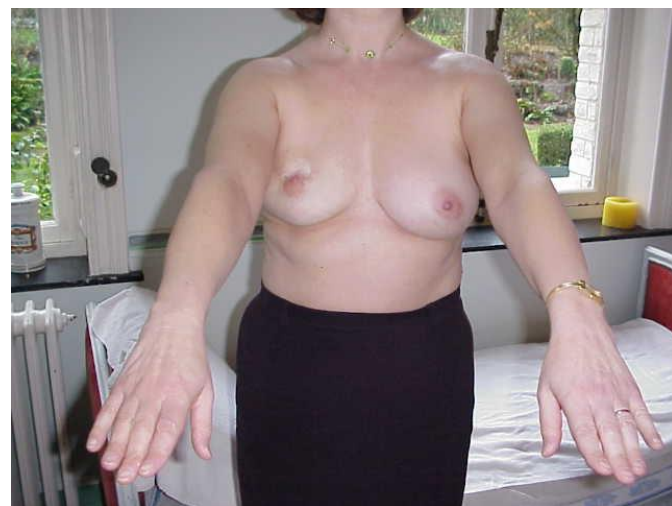
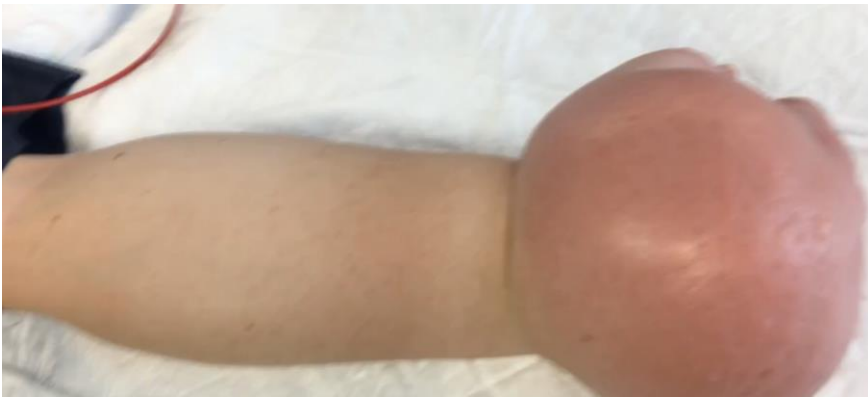**SAME RESULTS WITH ENLARGED ALNT COMBINED
WITH DIEP**

10Y POST OP

8Y P.OP

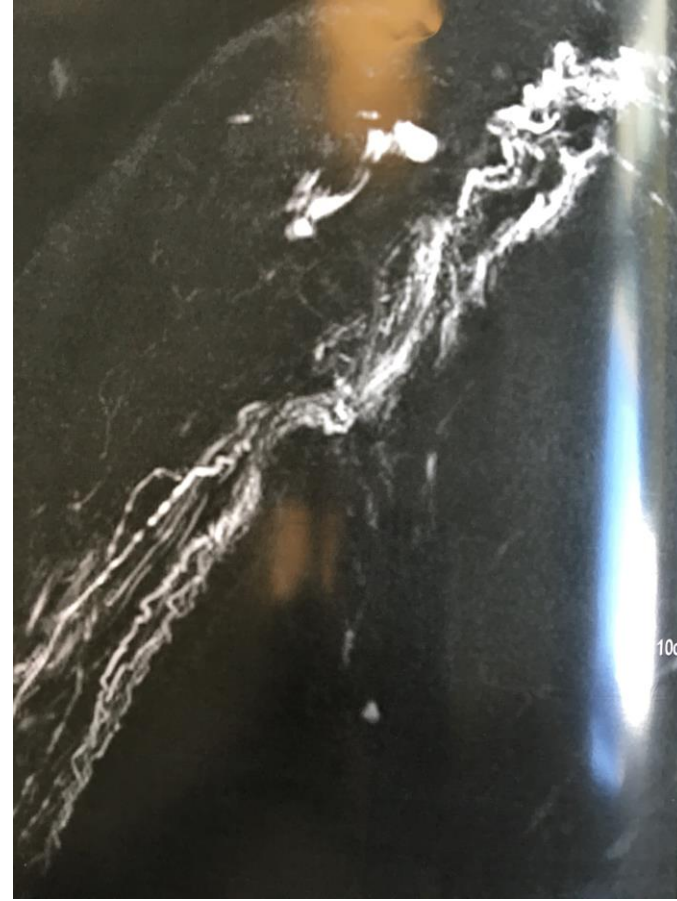
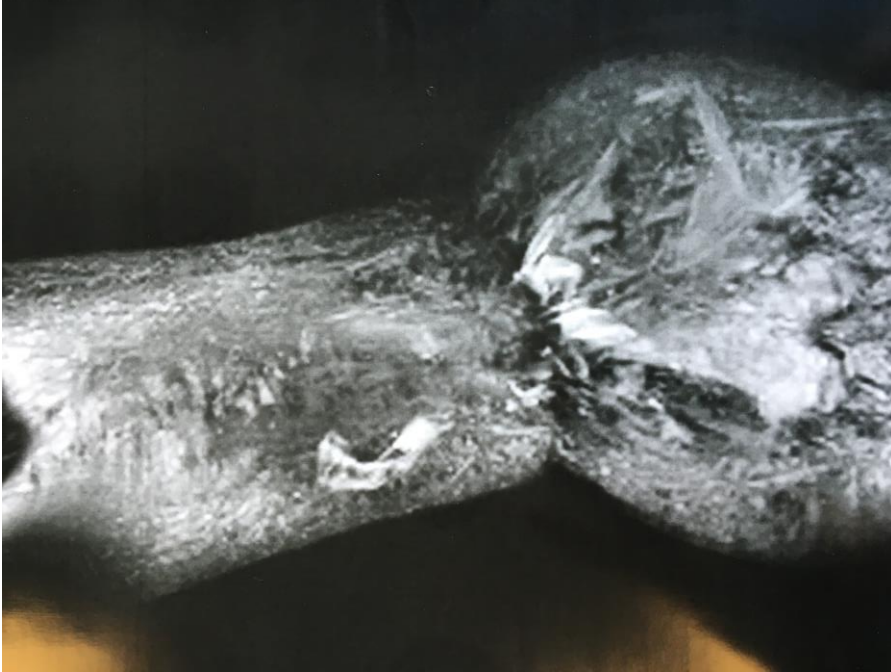10Y P.OP



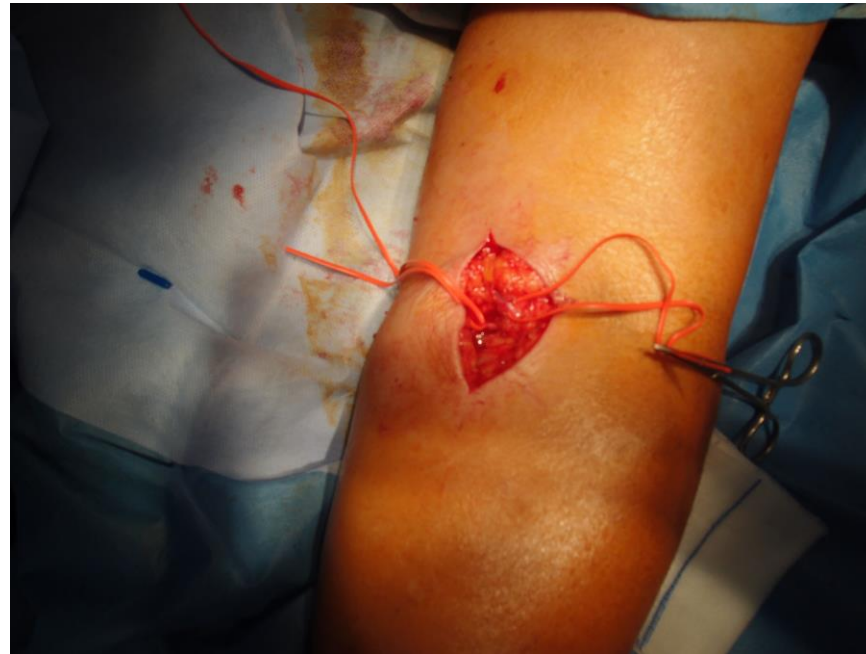


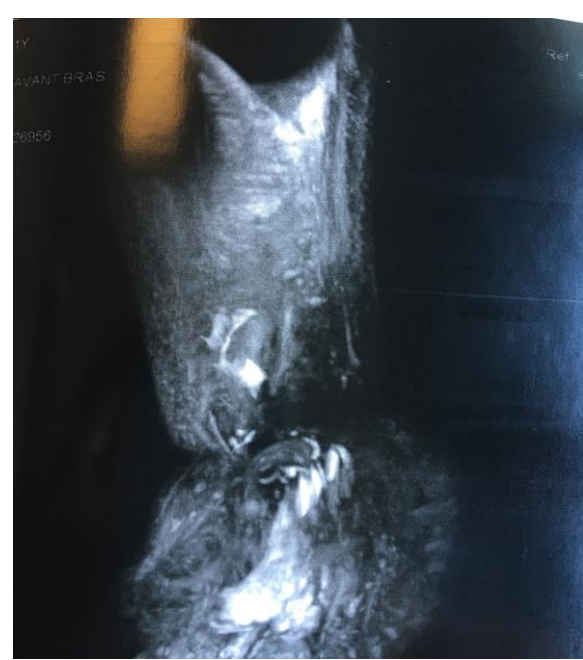
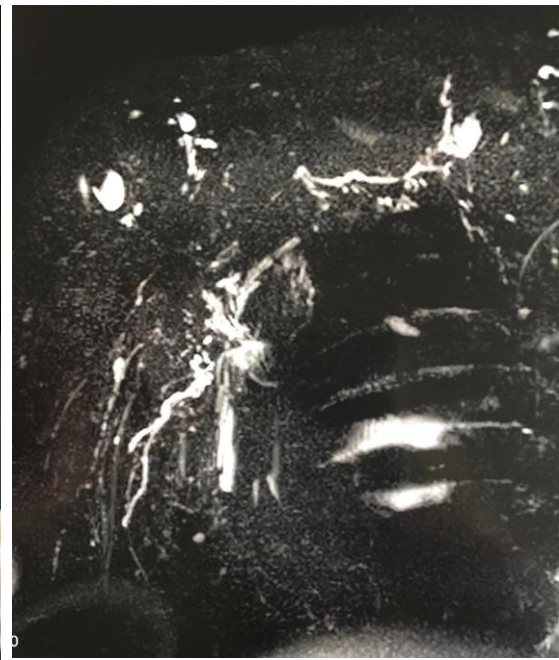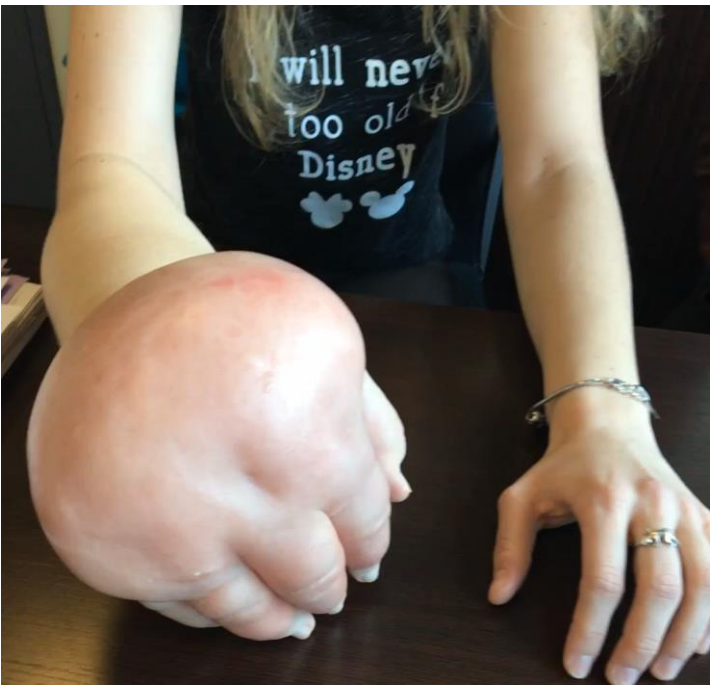DISTAL CONGENITAL LYMPHOEDEMA

- AFTER 1 TRAUMA, PERHAPS WEAKNESS OF THE LYMPHATIC SYSTEM....



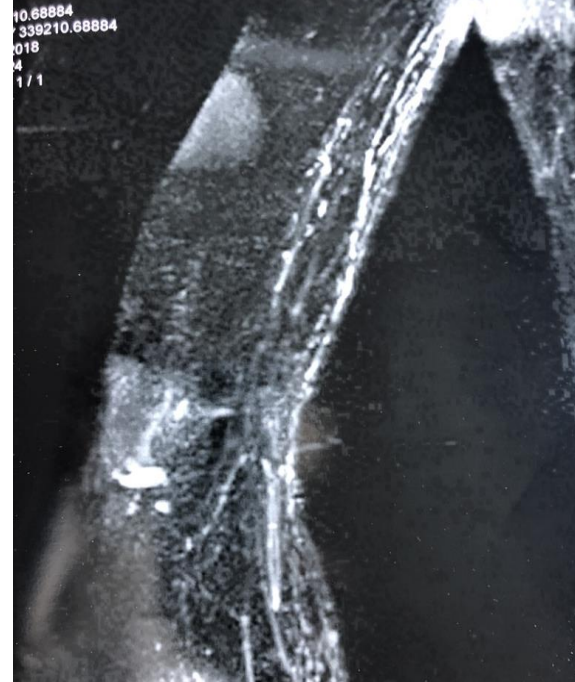
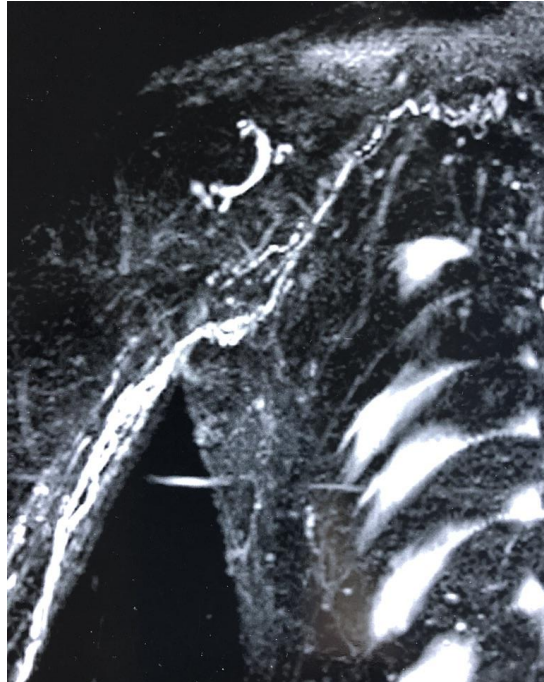
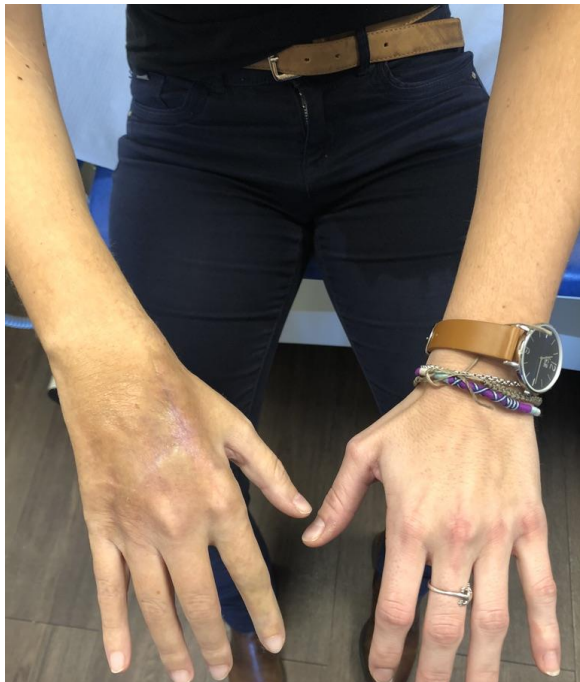INSERTION AT THE ELBOW IN CASE OF DISTAL LYMPHOEDEMA





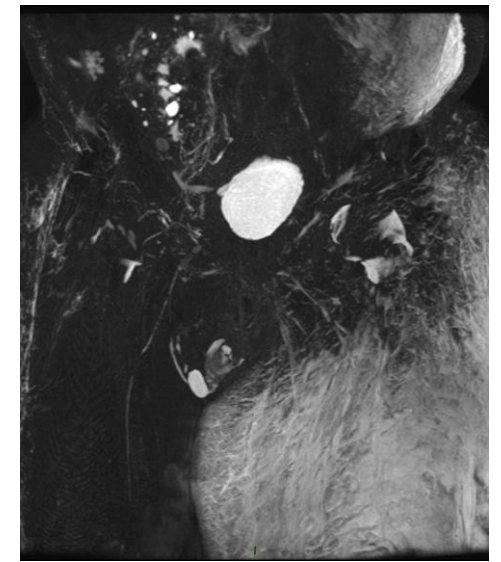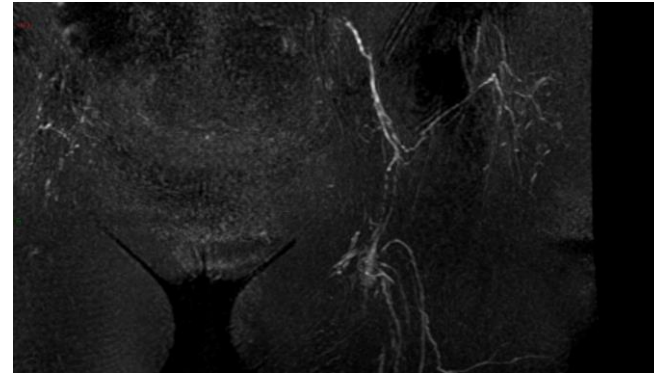
Preop and 18 months.

after the lymphnode transplantation

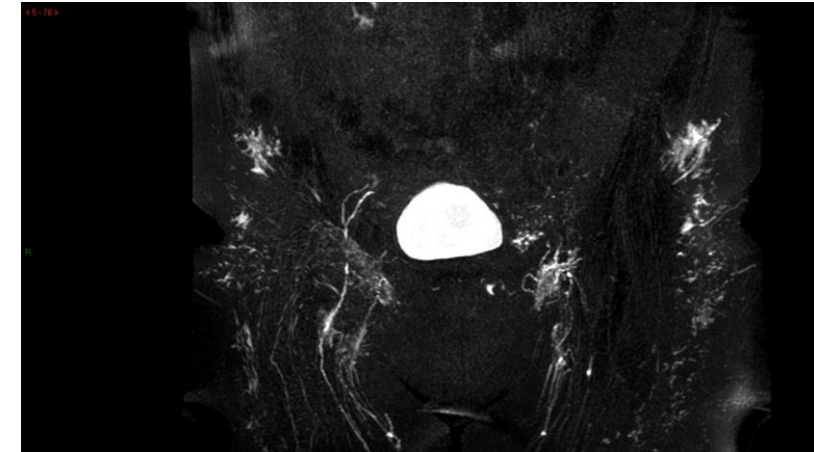
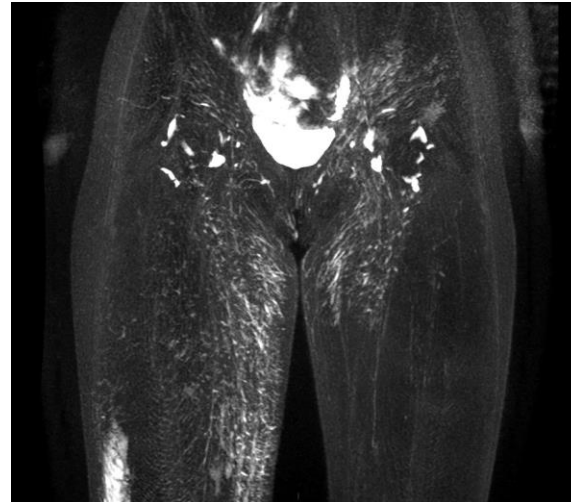


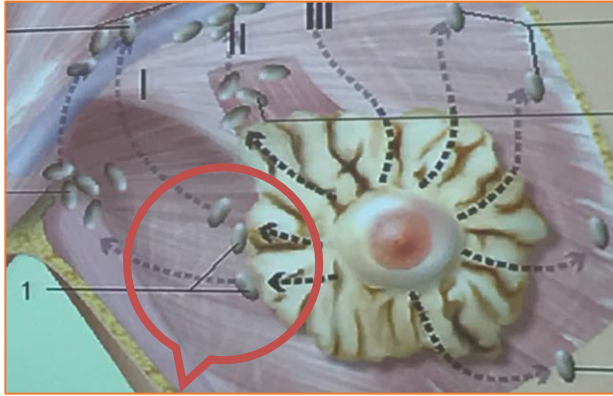
LOWER EXTREMITY
IATROGENIC
LYMPHOEDEMA

- **IATROGENIC LOWER LIMB**
 - **EVALUATION OF THE REMAINING PATHWAYS**
 - **IF THEY DO EXIST, TO IMPROVE THE RESULTS OF THE PHYSIOTHERAPY**
-

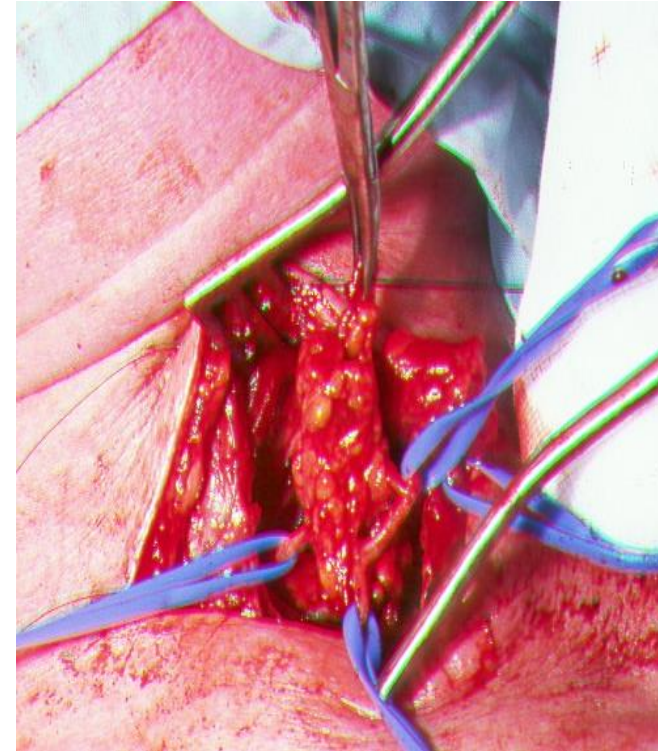
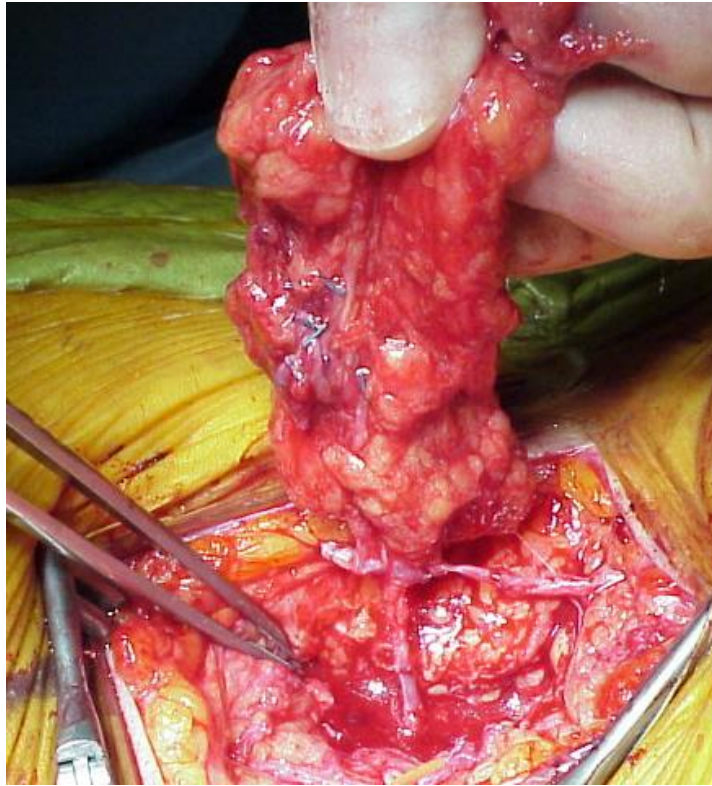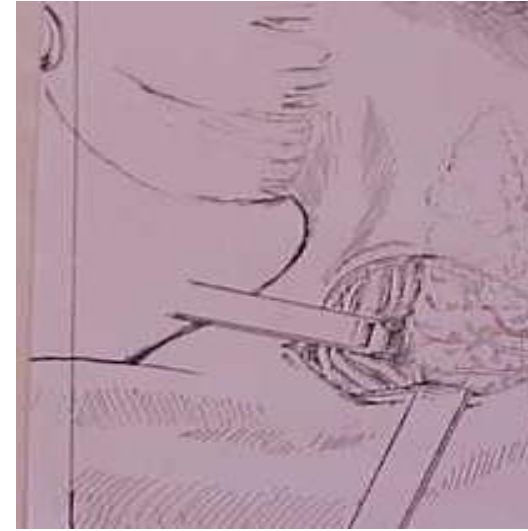


- **INDICATION OF RECONSTRUCTION IF NOT PATHWAYS**



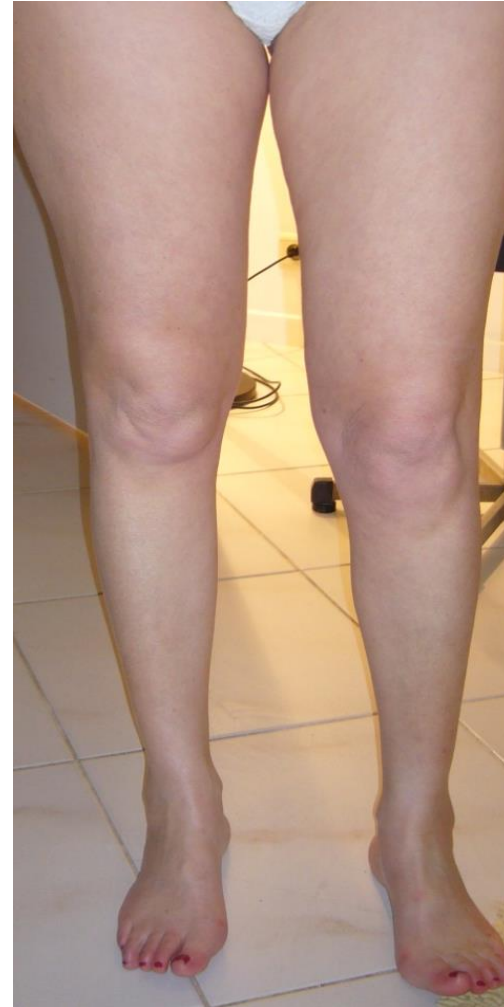
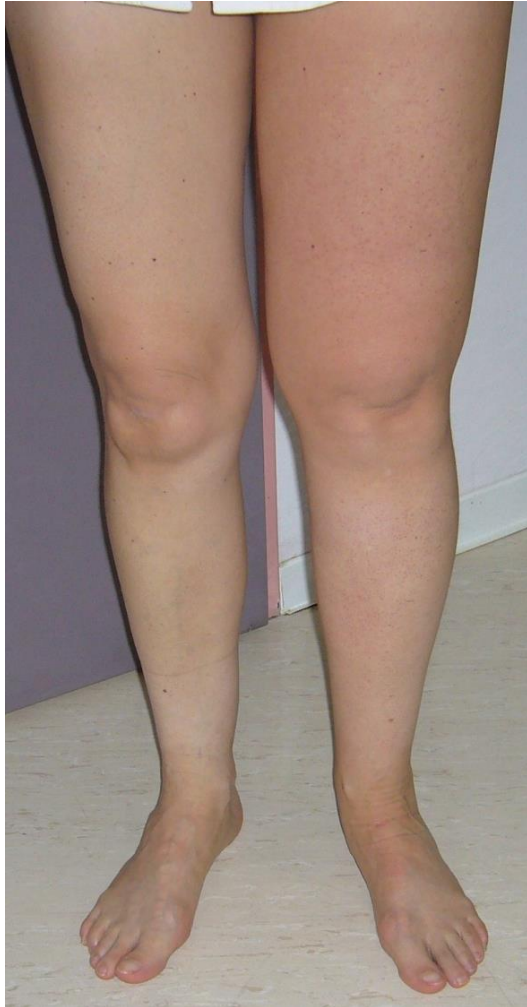
DONOR SITES

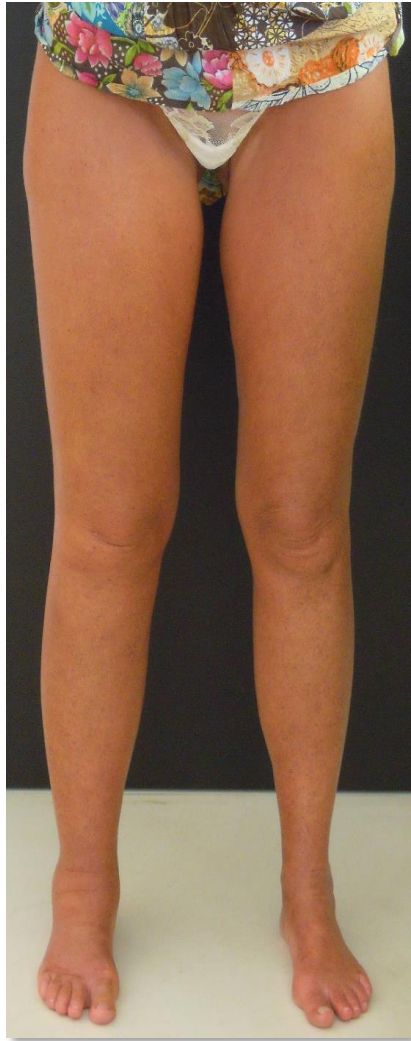

Grade 2:
lymphoedema Post hysterectomy

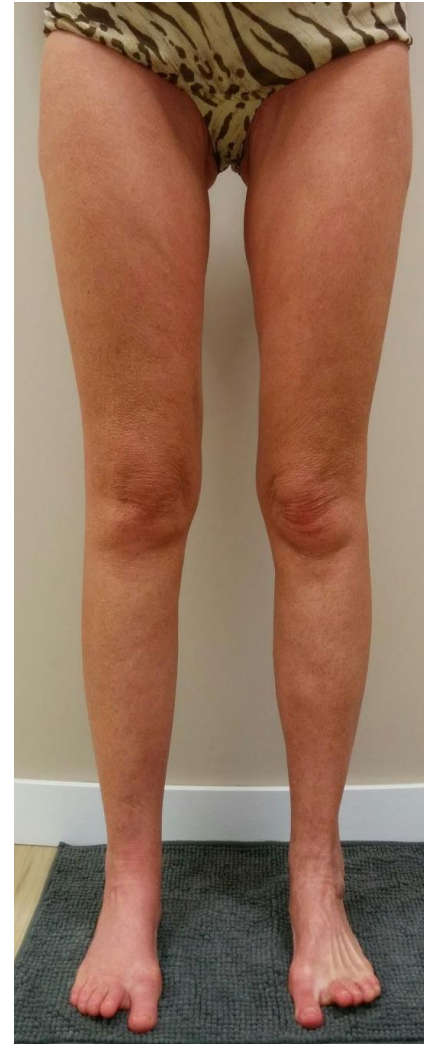2y .p.opALNT in deep inguinal region.



Results after lymphnodes transposition no more treatment and no sleeves 1 flap deeply inserted

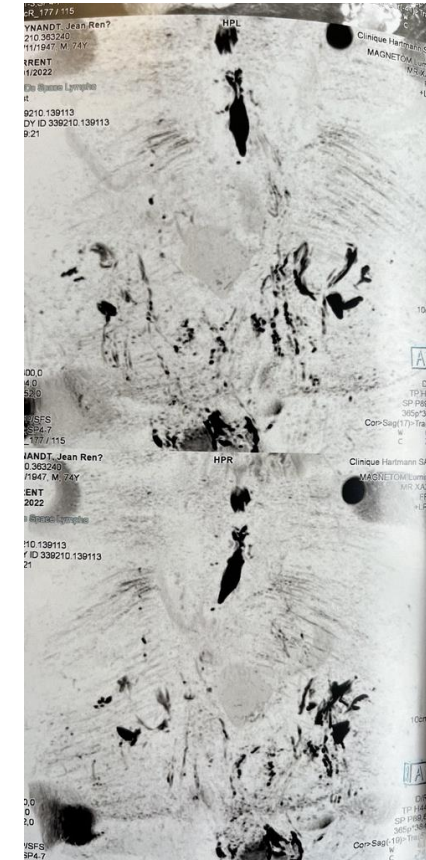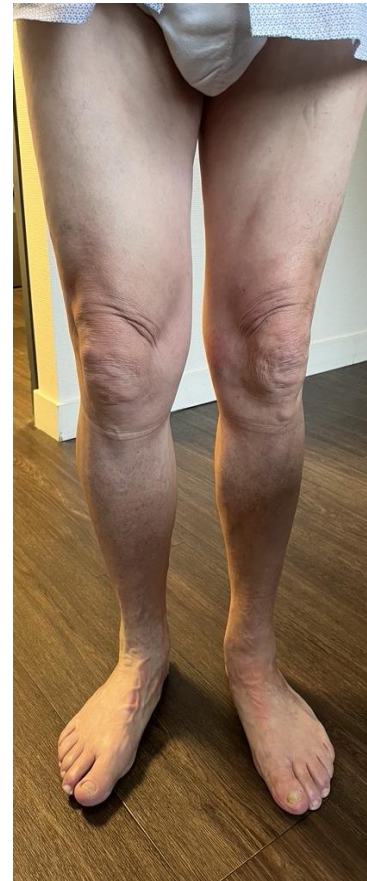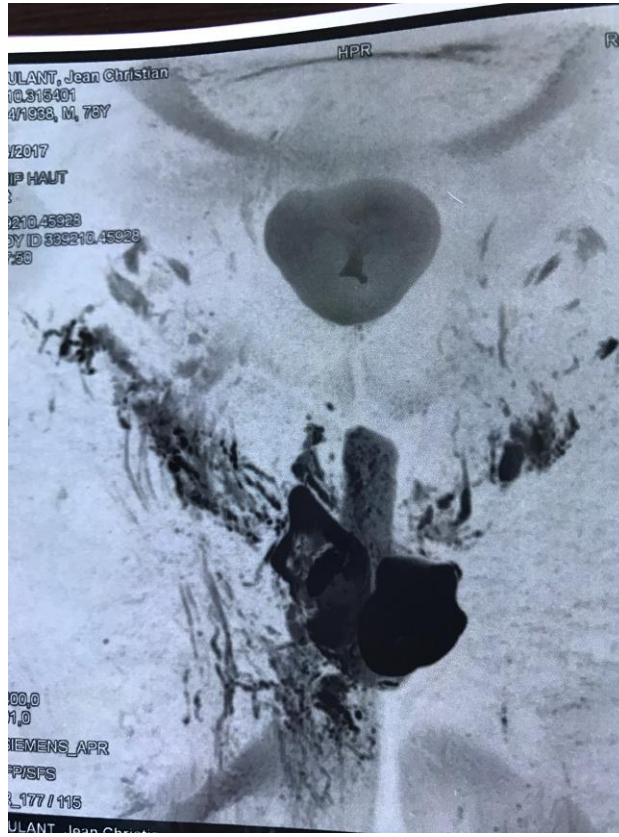


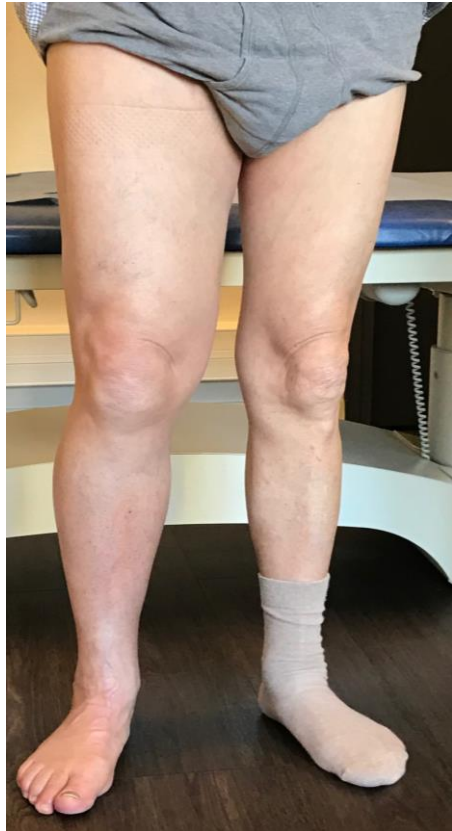Luglio
2014

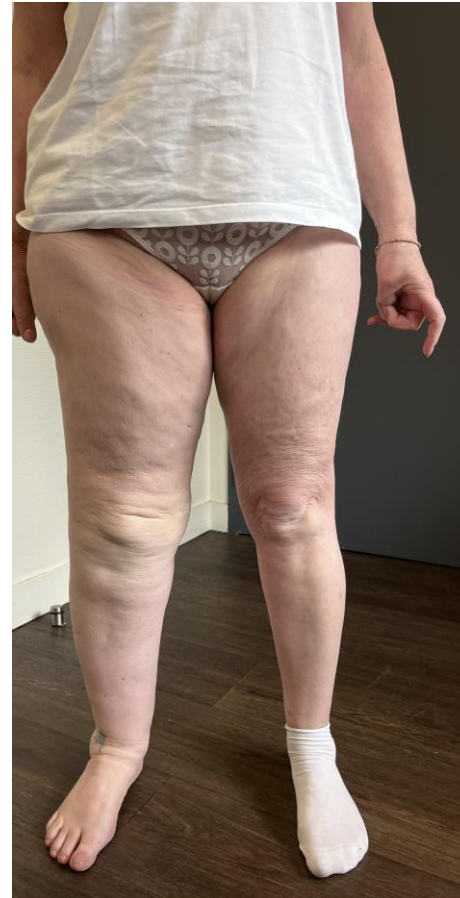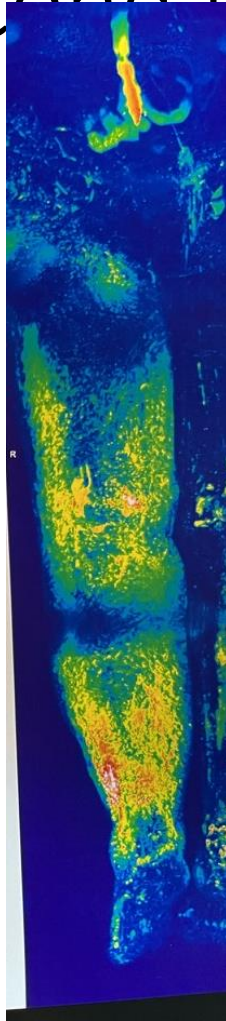

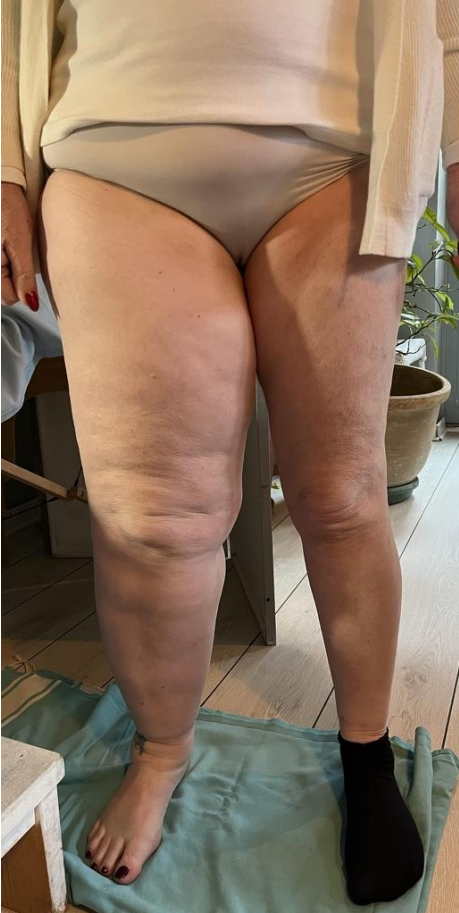
Dicembre
2015

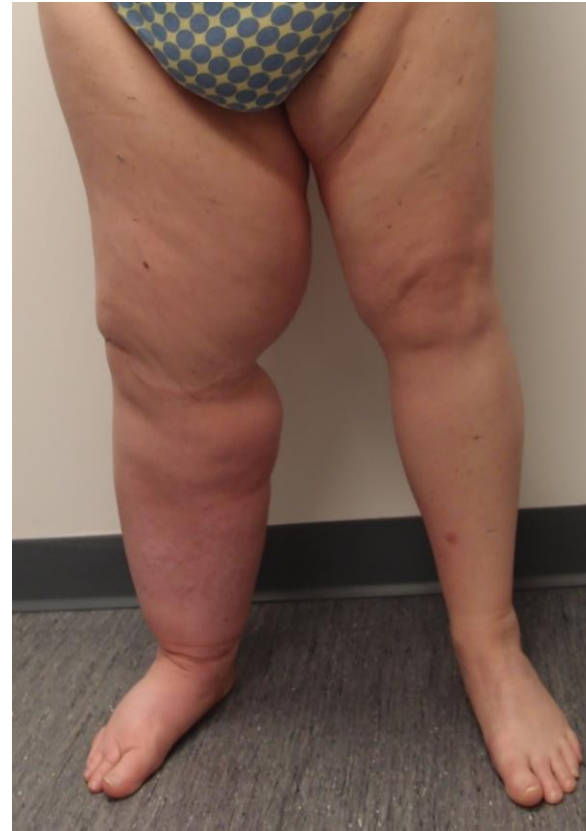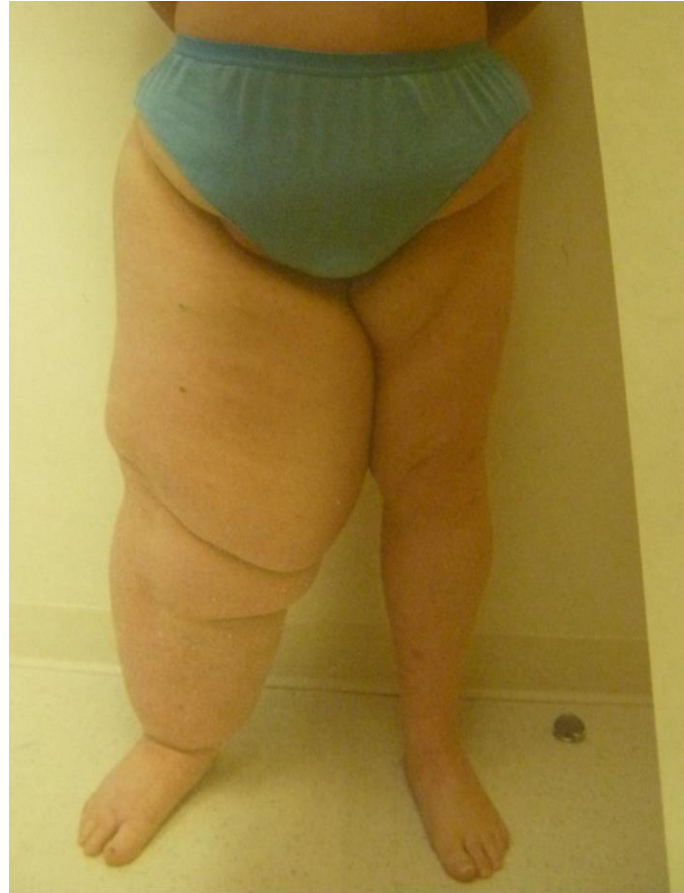Lymphoedema after radical prostatectomy. 1 year after ALNT



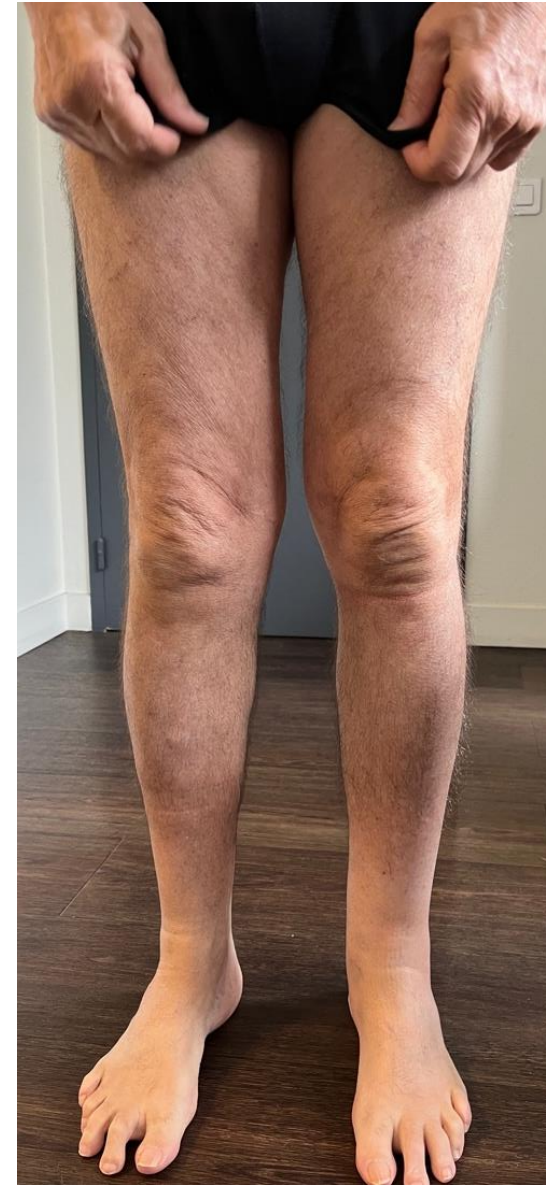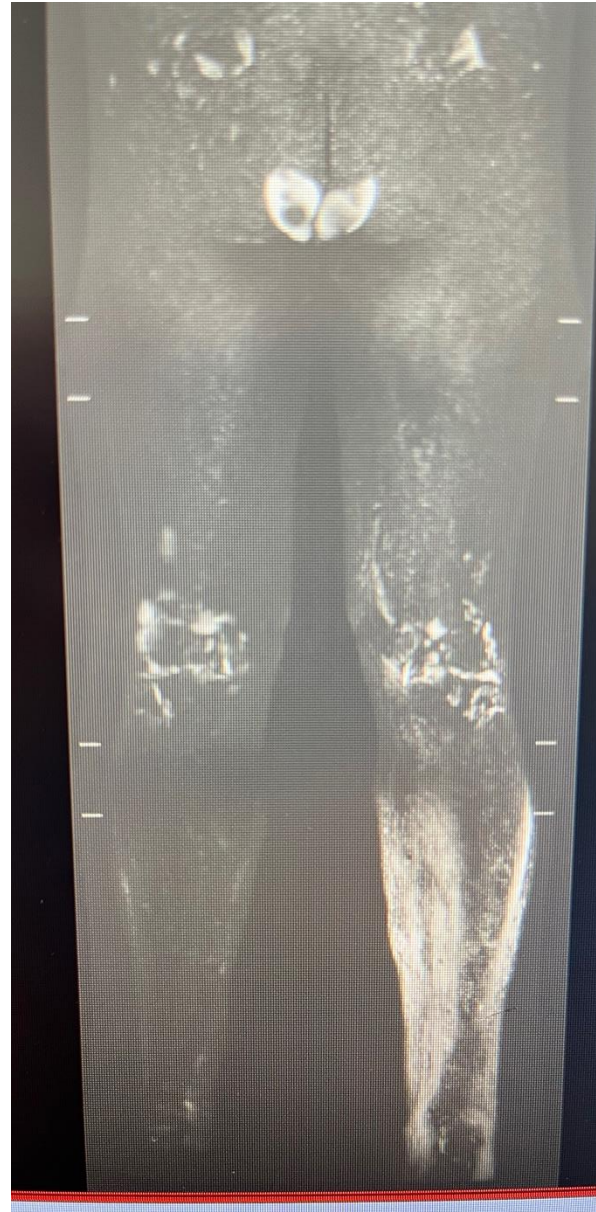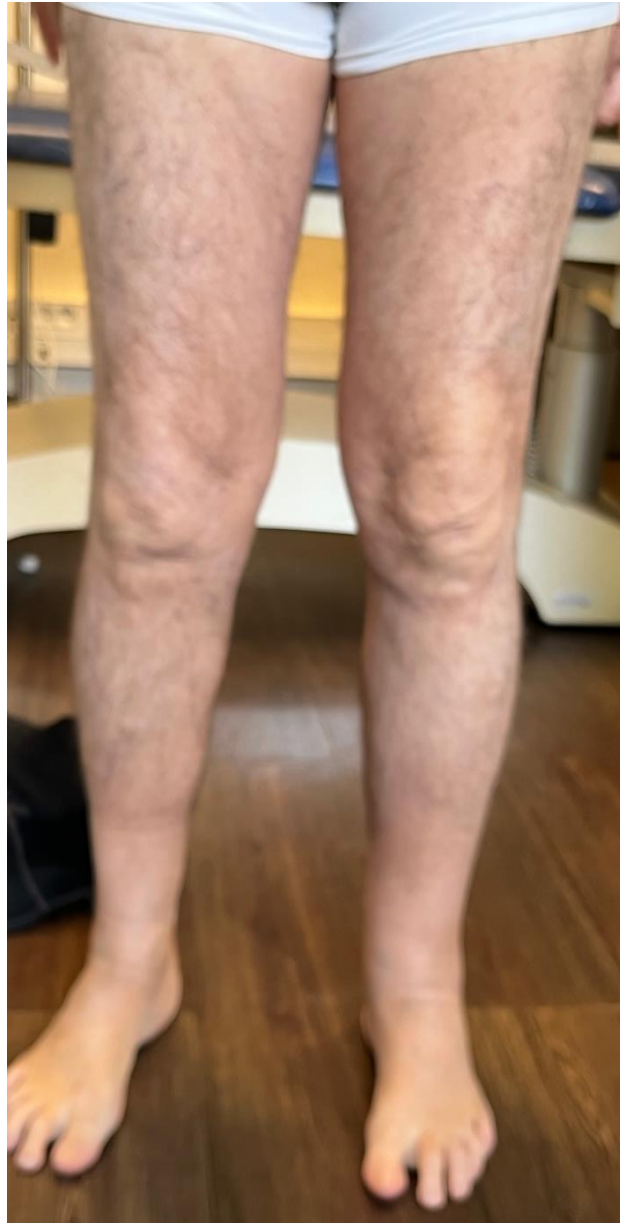Post hysterectomy 6 months after ALNT in deep inguinal region and liposculpture needs a second flap at the knee



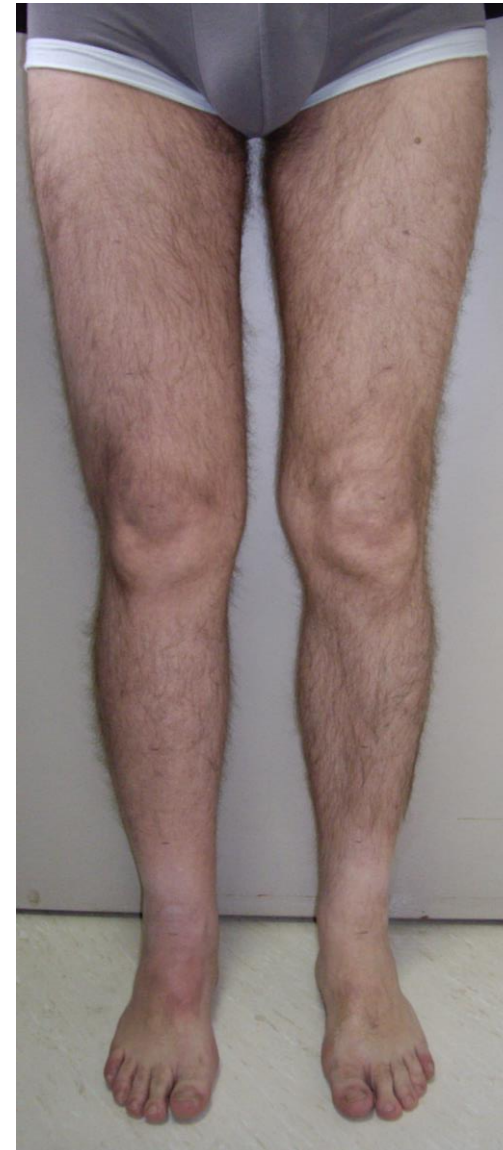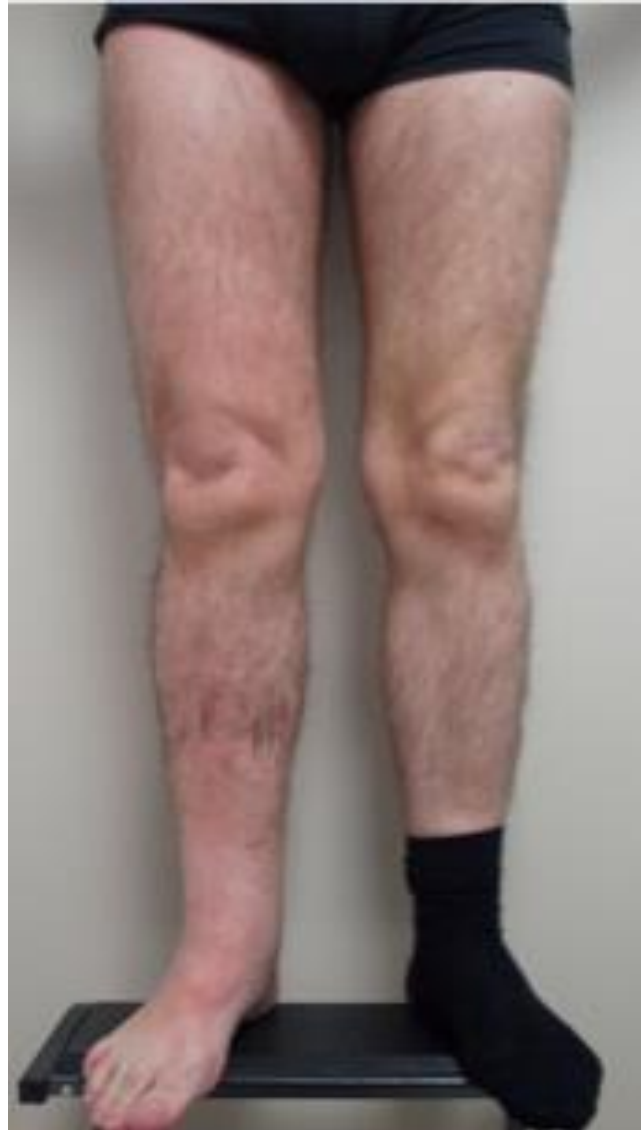RESULTS 8 MONTHS POST ALNT FOR LYMPHOEDEMA
POST TREATMENT FOR MELANOMA



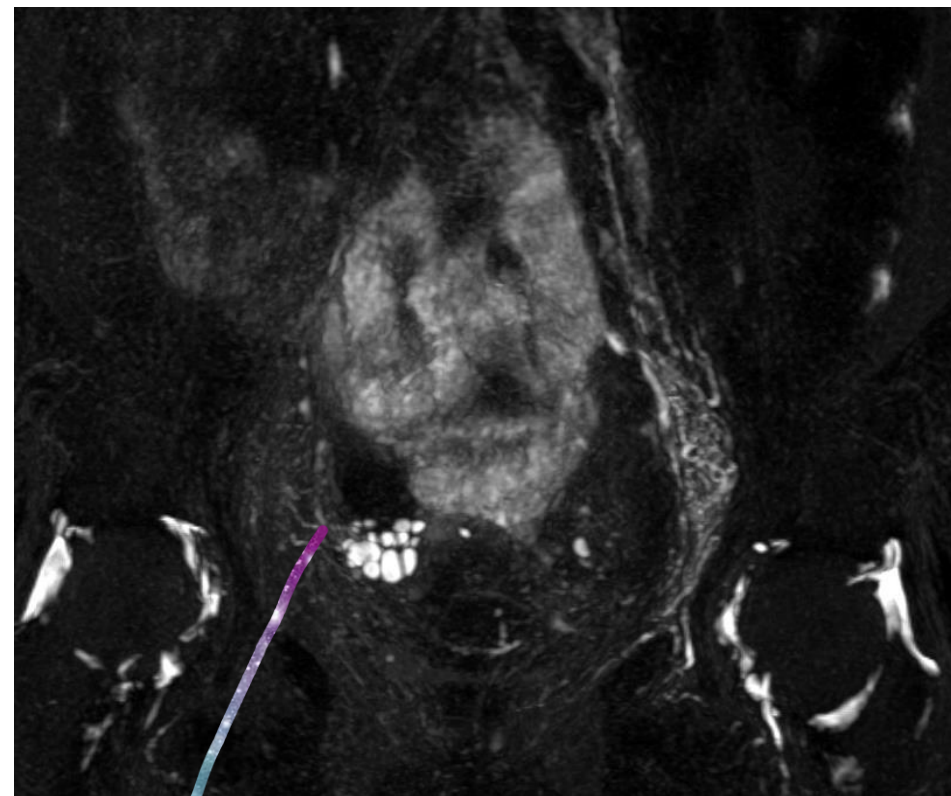
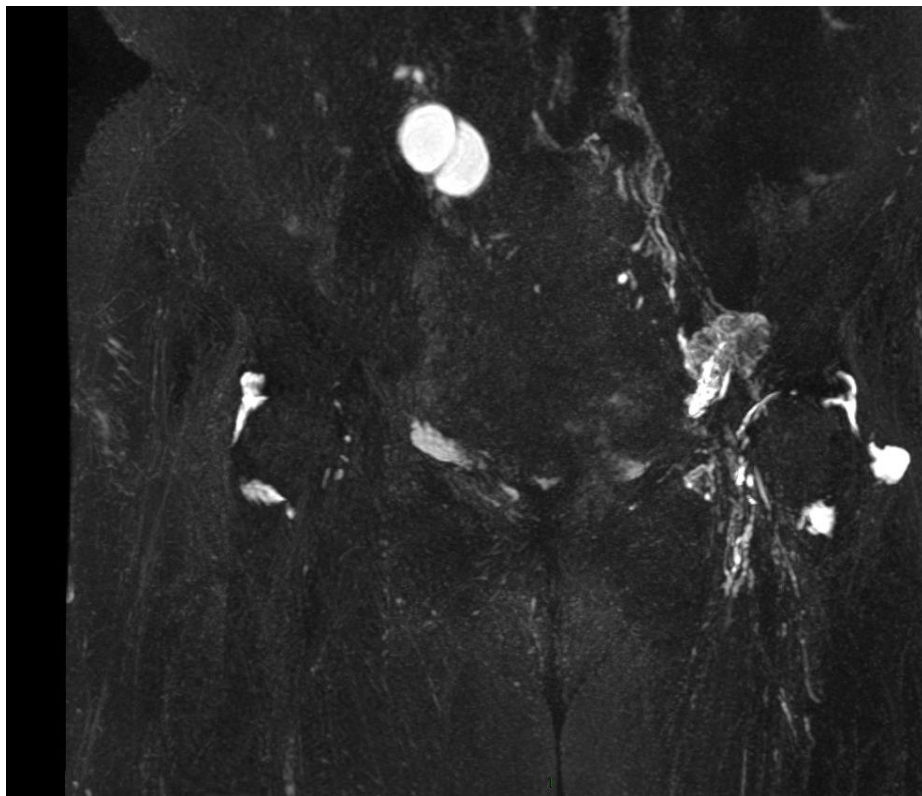
Lymphoedema post prostatectomy. 3 months after the lymphnodes transfer



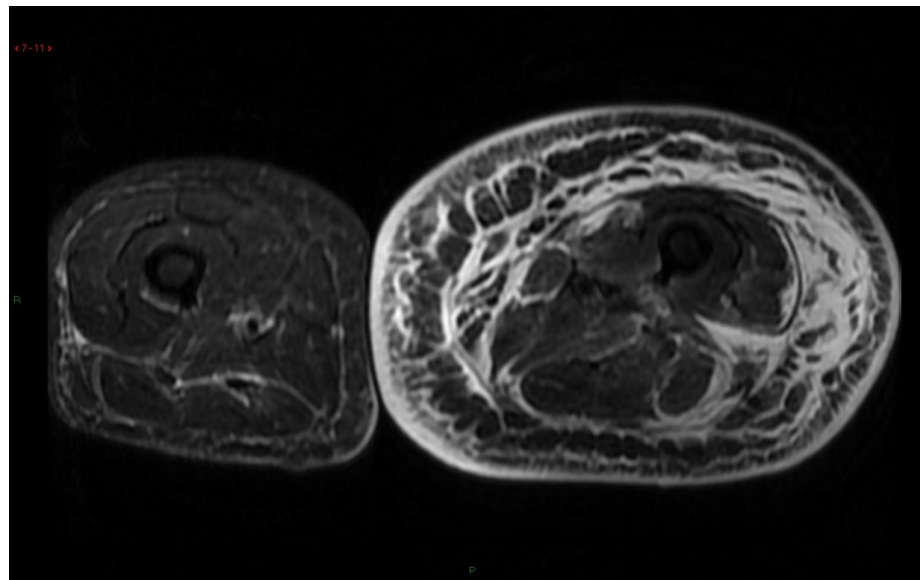
PREOP 11 YEARS OF LYMPHOEDEMA
AND 12 MONTHS AFTER LNT



PRE AND POST LYMPHNODES TRANSPLANTATION IN DEEP INGUNAL AREA



new vessels

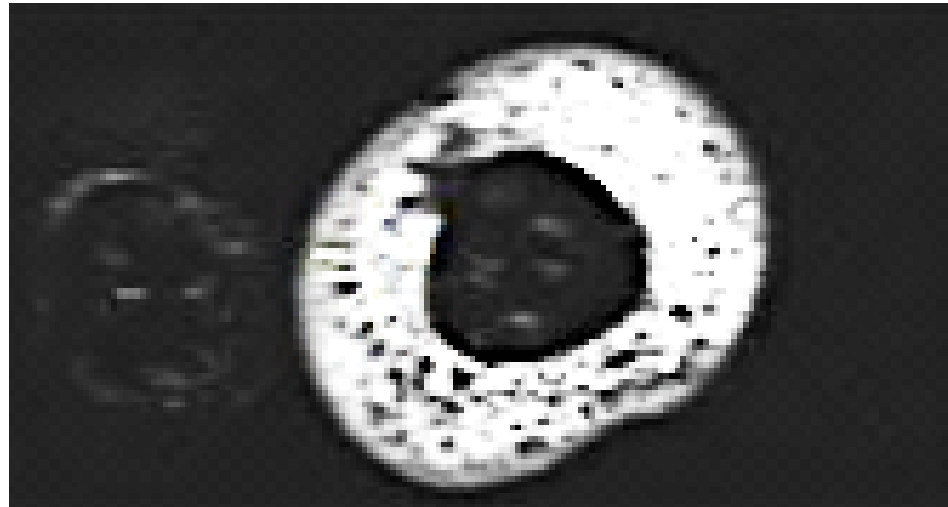


LMRI:


**MEASUREMENT OF THE
THICKNESS OF THE SKIN
, THE THICKNESS OF THE FAT**

THE % OF THE WATER IN THE FAT

=Best evaluation of the results

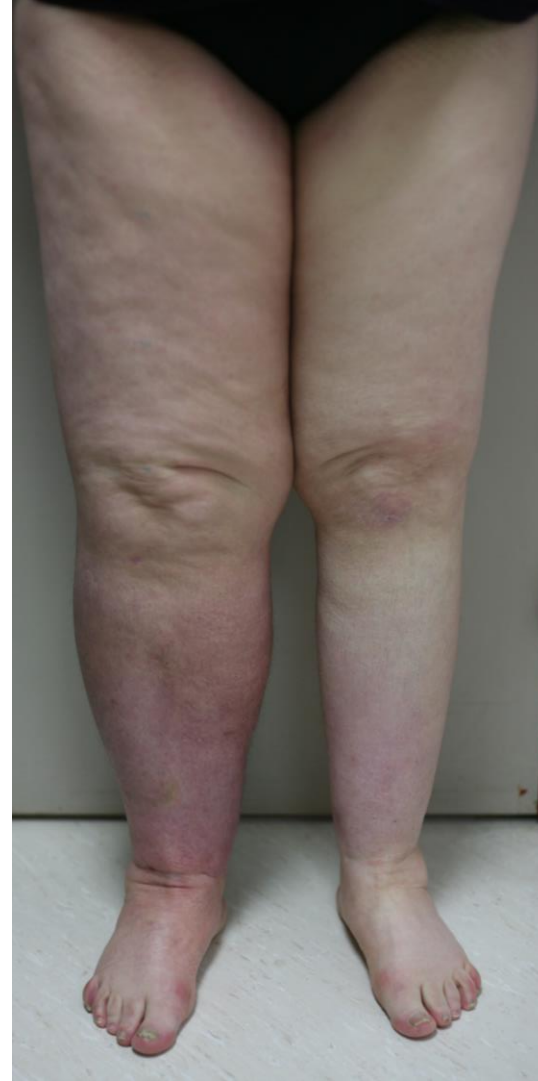
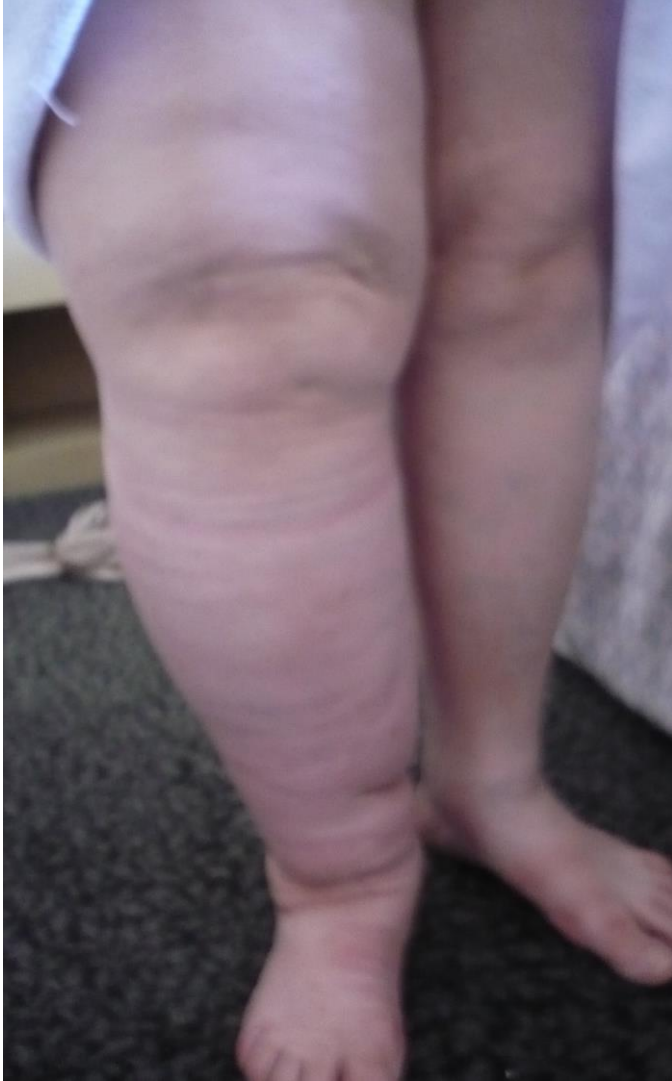
2015

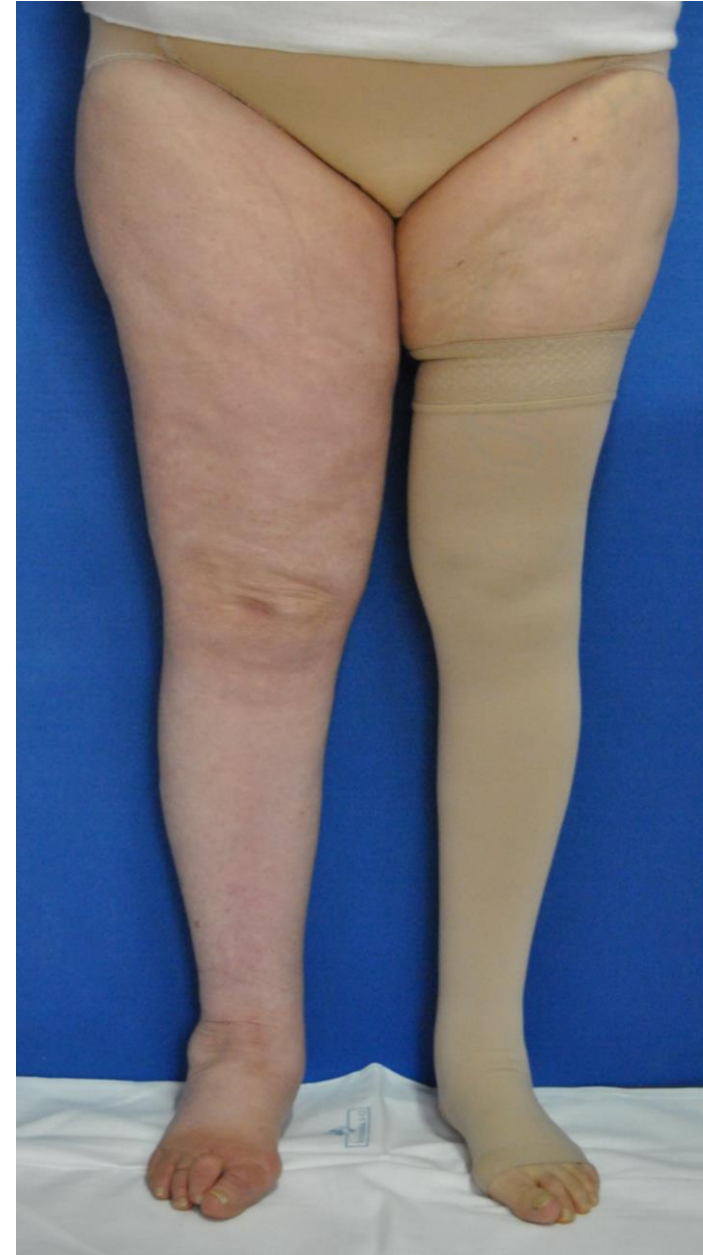
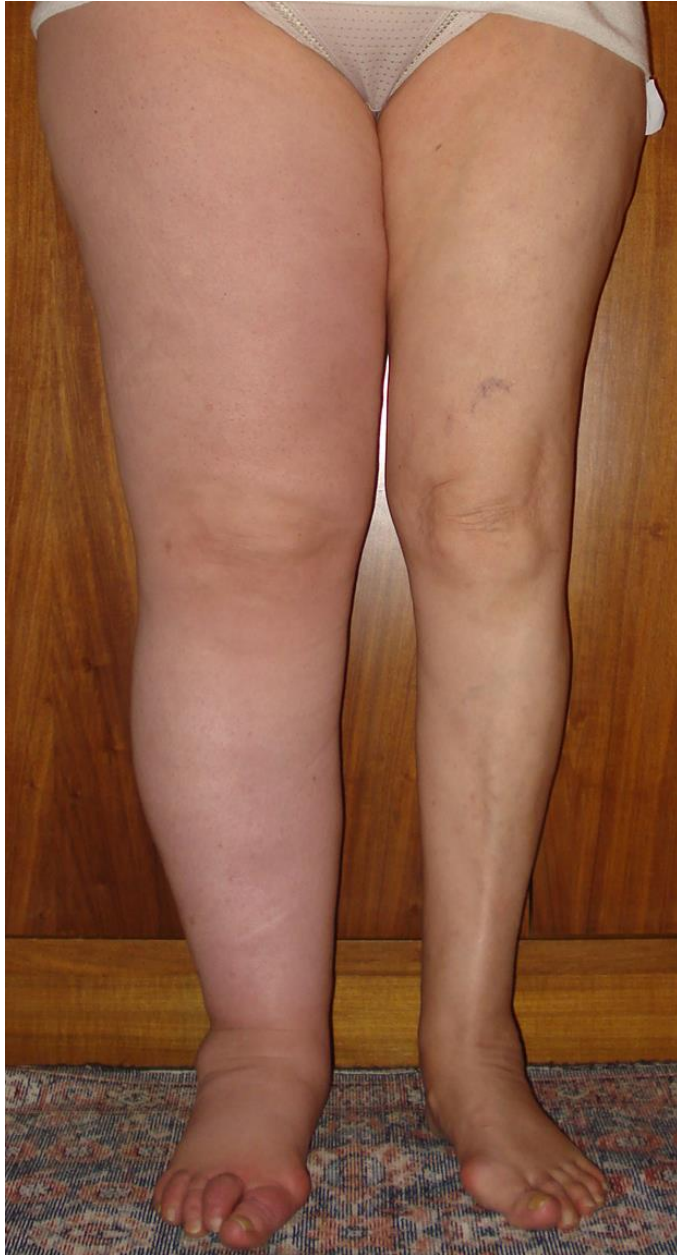
2016

**Works even in old lymphoedema chronic
infected she needs now liposculpture**



BIG LYMPHOEDEMA: 2 FLAPS IN INGUINAL AND AT THE KNEE LEVEL. LIPOSCUPTURE COMBINED FOR FAT DEPOSITS



Lipoedeme and lymphoedema post thigh lifting results after ALNT in inguinal liposculptures and correction of the scars

